

NAME: AWOSAN SAMUEL OLUWAGBENGA

MATRIC NO: 17/MHS01/071

COLLEGE: COLLEGE OF MEDICINE AND HEALTH SCIENCES

DEPARTMENT: MEDICINE AND SURGERY

COURSE: NEUROHISTOLOGY AND ANATOMY OF THE SPECIAL SENSES.

LECTURER: DR ADESHINA

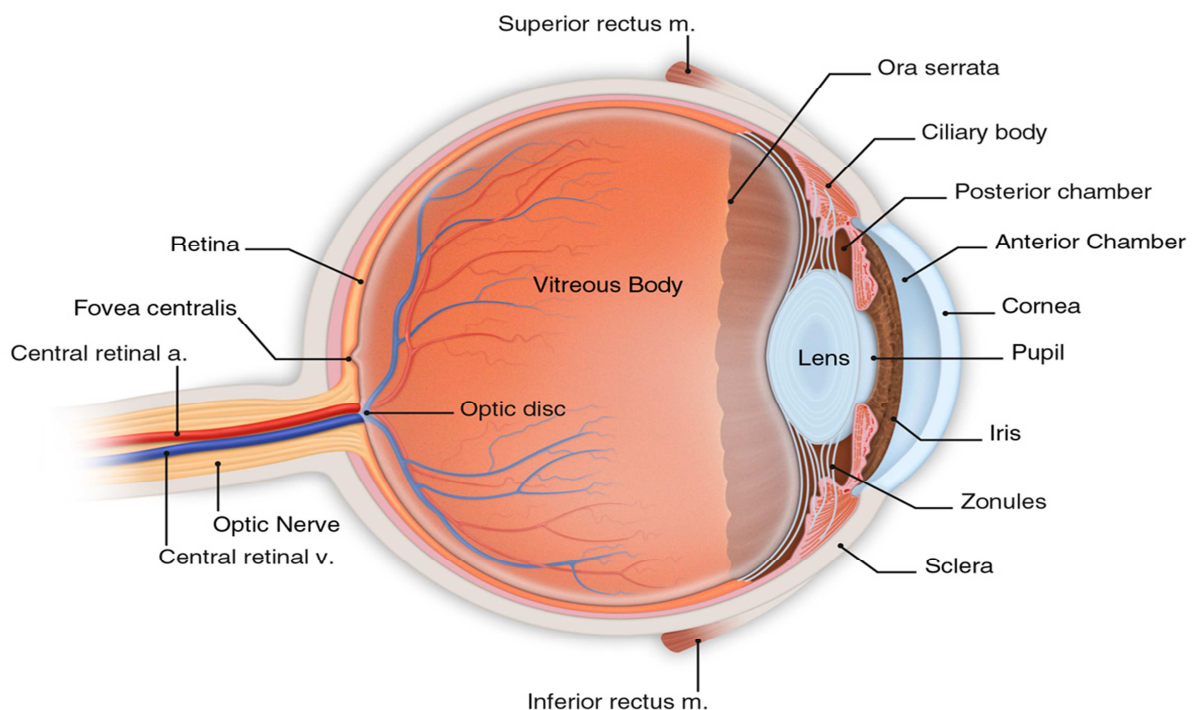
### **ASSIGNMENT**

1. Write an essay on the histological importance of the eye in relations to their cellular function.
2. Corona virus can penetrate the body through the eye and implicate the immune system. Briefly discuss the layers of the retina for information penetration.

## ANSWERS

### 1. INTRODUCTION: THE EYE

Eyes are organs of the visual system. They provide animals with vision, the ability to receive and process visual detail, as well as enabling several photo response functions that are independent of vision. Eyes detect light and convert it into electro-chemical impulses in neurons. In higher organisms, the eye is a complex optical system which collects light from the surrounding environment, regulates its intensity through a diaphragm, focuses it through an adjustable assembly of lenses to form an image, converts this image into a set of electrical signals, and transmits these signals to the brain through complex neural pathways that connect the eye via the optic nerve to the visual cortex and other areas of the brain.



External structures of the eye include the eyelashes, lids, muscles, accessory glands, and conjunctiva.

The internal structures of the eye consist of three layers of tissue arranged concentrically:

- The sclera and cornea make up the exterior layers.
- The uvea is the vascular layer in the middle, subdivided into the iris, ciliary body, and choroid.
- The retina constitutes the innermost layer and is made up of nervous tissue.

All of these layers can further subdivide and undergo histological classification. [

## **STRUCTURES OF THE EYE**

### **External Structures of the Eye:**

#### **1. Conjunctiva**

- The conjunctiva lines the inner part of the eyelids.
- The tarsal plate lies beneath the conjunctiva and contains meibomian glands, which secrete an oily substance to decrease the evaporation of the tear film.

2. **Tear film:** The tear film consists of aqueous, mucus, and oily secretions.

3. **Accessory glands:** Apocrine glands of Moll, meibomian glands, lacrimal glands.

4. **Muscles:** Orbicularis oculi, levator palpebrae superioris, superior tarsal muscle.

5. **Eyelid:** The eyelid, likewise known as the cover of the eye, a mobile layer made up of skin and also muscular tissue and also covers the eyeball.

### **Internal Structures of the Eye:**

The innermost structures of the eye are organized in the three layers as follows

#### **(A) Outermost Layer: Sclera and Cornea**

##### *1. The sclera (white of the eye)*

- The sclera is dense connective tissue made of mainly type 1 collagen fibers, oriented in different directions. The lack of parallel orientation of collagen fibers gives the sclera its white appearance, as opposed to the transparent nature of the cornea. However, the collagen of the sclera and cornea are continuous.
- The four layers of the sclera from external to internal are episclera, stroma, lamina fusca, endothelium.
- The episclera is the external surface of the sclera. It is connected to the Tenon capsule by thin collagen fibers. At the corneoscleral junction, also known as the limbus, the Tenon capsule contacts stroma of the conjunctiva.

## 2. Cornea (transparent front layer of the eye):

- Consists of type I collagen fibers oriented in a uniform parallel direction to maintain transparency
- **Consists of five layers:** epithelium (non-keratinized, stratified squamous epithelium), Bowman layer, stroma (also called substantia propria), Descemet's membrane, corneal endothelium.
- **Corneal epithelium:** fast growing, regenerating multicellular layer which interacts directly with the tear film.
- **Bowman layer:** This is a layer of subepithelial basement membrane protecting the underlying stroma. It is composed of type 1 collagen, laminin, and several other heparan sulfate proteoglycans.
- **Stroma**]: The largest layer of the cornea, the stroma has collagen fibers arranged in a regular pattern. Keratocytes maintain the integrity of this layer. The function of this layer is to maintain transparency, which occurs by the regular arrangement, and lattice structure of the fibrils, whereby scatter from individual fibrils gets canceled by destructive interference, and the spacing of less than 200 nm allows for transparency.
- **Descemet's membrane:** an acellular layer made of type IV collagen that serves as a modified basement membrane of the corneal endothelium
- **Corneal endothelium:** a one cell thick layer made of either simple squamous or cuboidal cells. Cells in this region do not regenerate and have pumps that maintain fluid balance and prevent swelling of the stroma. When corneal endothelial cells are lost, neighboring cells stretch to attempt to compensate these losses.

## (B)- "Middle Layer: Uvea (Iris, Ciliary Body, Choroid)":

### 1. "Iris":

- Consists of (1) stromal layer with pigmented, fibrovascular tissue and (2) pigmented epithelial cells beneath the stroma
- The sphincter pupillae and dilator pupillae muscles connect to the stroma
- The pigmented layer of cells blocks rays of light and ensures that light must move through the pupil to reach the retina
- The angle formed by the iris and cornea contains connective tissue with endothelial channels called the trabecular meshwork, which drains aqueous

humor in the anterior chamber into the venous canal of Schlemm. From here, fluid drains into episcleral veins.

2. "*Ciliary Body*": The tissue that divides the posterior chamber and vitreous body

- Consists of the ciliary muscle and the ciliary epithelium
- The ciliary muscle, via the lens zonules, controls the structure of the lens, which is vital for accommodation. Zonules are connective tissue fibers that connect the ciliary muscle and lens.
- The ciliary epithelium produces aqueous humor which fills the anterior compartment of the eye.

3. "*Choroid*":

- Consists of a dense network of blood vessels supplying nourishment to structures of the eye, housed in loose connective tissue.
- The choriocapillary layer is located in the innermost part of the choroid and supplies the retina
- The Bruch membrane is an extracellular matrix layer situated between the retina and choroid and has significance in age-related macular degeneration, where an accumulation of lipid deposits prevent diffusion of nutrients to the retina.

### **(C)- "Innermost layer: Lens, Vitreous, Retina":**

1. **Lens:** separates the aqueous and vitreous chambers

- Consists of an outer capsule, a middle layer called cortex, and an inner layer called the nucleus.
- The capsule is the basement membrane of the lens epithelium which lies below
- New lens cells differentiate from the lens epithelium and are incorporated peripherally, pushing older lens cells towards the middle.

2. **Vitreous:** a jelly-like space made of type II collagen separating the retina and the lens

3. **Retina:** nervous tissue of the eye where photons of light convert to neurochemical energy via action potentials

Moreover, the retina itself is divided into various layers as follows :

- **Retinal pigment epithelium:** made of cuboidal cells containing melanin which absorbs light. These cells also establish a blood-retina barrier through tight junctions.

- **Rod and cone cells:** the layer of cells with photoreceptors and glial cells. Rods are located peripherally and are more sensitive to light and motion than cones. Cones have higher visual acuity and specificity for color vision.
- **Outer limiting membrane:** a layer of Muller cells and rod/cone junctions which serves to separate the photosensitive regions of the retina from the areas that transmit the electrical signals.
- **Outer nuclear layer:** This layer consists of nuclei of rod and cone cells.
- **Outer plexiform layer:** This layer contains synaptic processes of rod and cone cells.
- **Inner nuclear layer:** This layer contains the cell body of glial, amacrine, bipolar, and horizontal cells
- **Inner plexiform layer:** This layer relays information from cells of the inner nuclear layer. Thus, this layer has axons of amacrine, bipolar, and glial cells and dendrites of retinal ganglion cells.
- **Ganglion cell layer:** This layer contains nuclei of retinal ganglion cells.
- **Nerve fiber layer:** This layer contains axons of retinal ganglion cells and the astroglia which support them. Collectively, these axons constitute the optic nerve.
- **Internal limiting membrane:** A thin layer of Muller glial cells and basement membrane which demarcates the vitreous anteriorly from the retina posteriorly.

## **2. THE RETINA**

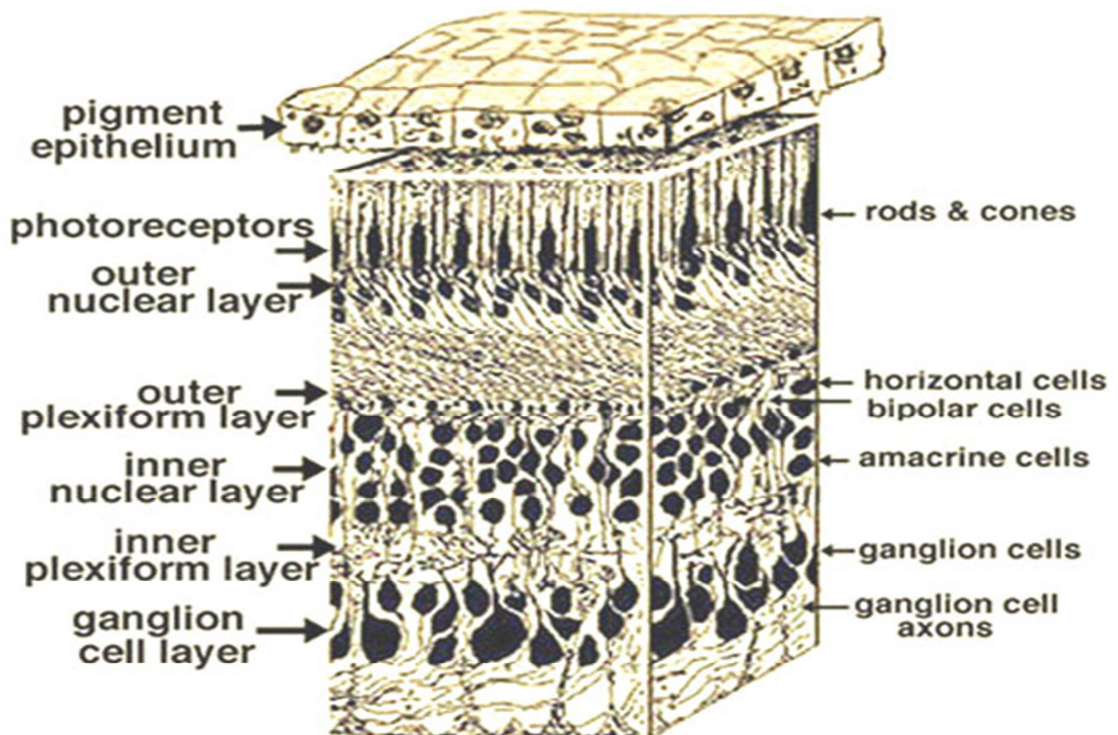
The retina is the innermost layer in the eye that is responsible for the visual processing that turns light energy from photons into three-dimensional images. Located in the posterior portion of the eyeball, the retina is the only extension of the brain that can be viewed from the outside world and gives ophthalmologists a rare window into real-time pathology affecting the retina. Development of the retina is a long and complex process that begins during the fourth week of embryogenesis and continues into the first year of life. This long and complex embryonic development makes the retina vulnerable to genetic and environmental insults that can negatively affect retinal development. Retinal tissue develops to become the most metabolically expensive tissue in the human body, consuming oxygen more rapidly than any other tissue. The retina is fed oxygen from a unique dual blood supply that divides the retina into outer and inner layers for more efficient oxygenation. The retina itself consists of six different cell lines divided into ten different layers, each playing a specific role in creating and transmitting vision. The different cell types perform a particular role

and form functional circuits that specialize in detecting specific variations and movements of light.

The pathway through which information passes through the retina to enter into the eyes is through the layers of the retina. There are ten different layers of the retina which are made up of six major cell types.

1. Rods
2. Cones
3. Retinal Ganglion cells
4. Bipolar cells
5. Horizontal cells
6. Amacrine cells

The various layers of the retina arranged from the outermost to the innermost is the pathway through which information penetration occurs. They are;



*Fig. 4. 3-D block of a portion of human retina.*

### **1. Retinal pigment epithelium**

The retina is supported by the retinal pigment epithelium (RPE), which has many functions including vitamin A metabolism, maintenance of the blood-retina barrier, phagocytosis of photoreceptor outer segments, production of mucopolysaccharide matrix surrounding the outer segments of the retina, and active transport of materials into and out of the RPE.

### **2. Rod and cone cells ( The photoreceptor layer)**

The layer of cells with photoreceptors and glial cells. Rods are located peripherally and are more sensitive to light and motion than cones. Cones have higher visual acuity and specificity for color vision.

### **3. External limiting membrane**

This layer contains the bases of the rod and cone photoreceptors cell bodies. The ELM forms a barrier between the subretinal space, into which the inner and outer segments of rods and cones project to be in close association with the pigment epithelial layer behind the retina, and the neural retina proper.

### **4. Outer nuclear layer**

This layer contains the rod and cone granules that sense photon, extensions from the rod, and cone cell bodies.

### **5. Outer plexiform layer**

This layer of the retina contains a neuronal synapse of between rods and cones with the footplate of horizontal cells. Capillaries are also found to be primarily running through the outer plexiform layer.

### **6. Inner nuclear layer**

This layer of the retina contains the cell bodies of bipolar cells, horizontal cells, and amacrine cells.

### **7. Inner plexiform layer**

The inner plexiform layer is an area comprised of a dense reticulum of fibrils formed by interlaced dendrites of Retinal Ganglion Cells and cells of the inner nuclear layer.

### **8. Ganglion cell layer**

This layer contains the retinal ganglion cells (RGCs) and displaced amacrine cells. As a rule of thumb, smaller RGCs dendrites arborize in the inner plexiform layer while larger RGCs dendrites arborize in other layers.



### **9. Nerve fiber layer (NFL)**

The nerve fiber layer is the second innermost layer of the retina from the vitreous. Patients with retinitis pigmentosa may have a measurable degree of RNFL thinning as determined by OCT.

### **10. Inner limiting membrane**

The ILM is the retina's inner surface bordering the vitreous humor and thereby forming a diffusion barrier between the neural retina and vitreous humor. The ILM contains laterally contacting Muller cell synaptic boutons and other basement membrane parts.