

Tongue

Name: Okafor Vanessa

Matric number: 17/mhs01/242

Course: Anatomy 301

Department: Medicine and surgery

Question 1

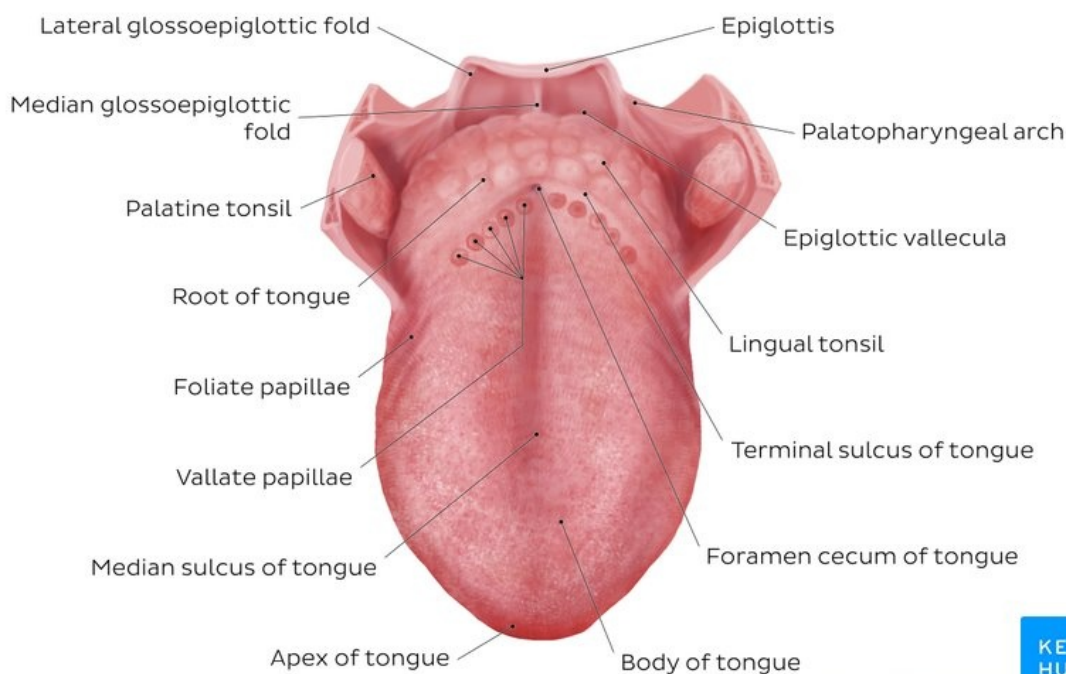
Discuss the anatomy of the tongue and comment on its clinical application

The tongue is a pink, muscular organ located within the oral cavity proper. It is kept moist by the products of the major and minor **salivary glands**, which aids the organ as it facilitates deglutition, speech, and gustatory perception. While there is significant variability in the length of the tongue among individuals, on average, the organ is roughly 10 cm long. It has three main parts:

The **tip or apex** of the tongue is the most anterior, and most mobile aspect of the organ.

The tip is followed by the **body** of the tongue. It has a **rough dorsal (superior) surface** that abuts the palate and is populated with taste buds and lingual papillae, and a **smooth ventral (inferior) surface** that is attached to the floor of the oral cavity by the lingual frenulum.

The **base** of the tongue is the most posterior part of the organ. It is populated by numerous lymphoid aggregates known as the lingual tonsils along with foliate papillae along the posterolateral surface.



There are numerous important structures surrounding the tongue. It is limited anteriorly and laterally by the upper and lower rows of **teeth**. Superiorly, it is bordered by the **hard** (anterior part) and **soft** (posterior part) **palates**. Inferiorly, the root of the tongue is continuous with the **mucosa** of the floor of the oral cavity; with the **sublingual salivary glands** and vascular bundles being located below the mucosa of the floor of the oral cavity.

The **palatoglossal** and **palatopharyngeal arches** (along with the palatine tonsils) have lateral relations to the posterior third of the tongue. Posterior to the base of the tongue is the dorsal surface of the **epiglottis** and **laryngeal inlet**, and the posterior wall of the oropharynx. As mentioned earlier, the presulcal and postsulcal parts of the tongue differ not only by anatomical location, but also based on embryological origin, innervation, and the type of mucosa found on its surface.

Anterior two thirds

The presulcal tongue includes the **apex** and **body** of the organ. It terminates at the **sulcus terminalis**; which can be seen extending laterally in an oblique direction from the foramen cecum towards the palatoglossal arch. The mucosa of the dorsal surface of the oral tongue is made up of **circumvallate**, **filiform**, and **fungiform papillae**. There is also a **longitudinal midline** groove running in an anteroposterior direction from the tip of the tongue to the foramen cecum. This marks the embryological point of fusion of the lateral lingual swellings that formed the oral tongue. It also represents the location of the **median lingual (fibrous) septum** of the tongue that inserts in the body of the hyoid bone.

On the lateral surface of the oral tongue are **foliate papillae** arranged as a series of vertical folds. The ventral mucosa of the oral tongue is comparatively unremarkable. It is smooth and continuous with the mucosa of the floor of the mouth and the inferior gingiva. The **lingual veins** are relatively superficial and can be appreciated on either side of the **lingual frenulum**. Lateral to the lingual veins are pleated folds of mucosa known as the **plica fimbriata**. They are angled anteromedially toward the apex of the tongue.

Posterior third

The remainder of the tongue that lies posterior to the sulcus terminalis is made up by the **base** of the organ. It lies behind the palatoglossal folds and functions as the anterior wall of the oropharynx. Unlike the oral tongue, the pharyngeal tongue does not have any lingual papillae. Instead, its mucosa is populated by aggregates of lymphatic tissue known as the **lingual tonsils**. The mucosa is also continuous with the mucosa of the laterally located palatine tonsils, the lateral oropharyngeal walls, and the posterior epiglottis and glossoepiglottic folds.

Muscles

The tongue is chiefly a muscular organ with some amount of fatty and fibrous tissue distributed throughout its substance. All the muscles of the tongue are paired structures, with each copy being found on either side of the median fibrous septum. There are muscles that extend outside of the organ to anchor it to surrounding bony structures, known as **extrinsic muscles**. The other set of muscles are confined to each half of the organ and contribute to altering the shape of the organ; these are the **intrinsic muscles**.

Intrinsic tongue muscles

The intrinsic tongue muscles are responsible for adjusting the **shape** and **orientation** of the organ. It is made up of four paired muscles, which are discussed below in a dorsoventral manner.

The **superior longitudinal muscles** are made up of a thin layer of muscle fibers traveling in a mixture of oblique and longitudinal axes just deep to the superior mucosal surface of the organ. These fibers arise from the **median fibrous septum** as well as the **fibrous layer of submucosa** from the level of the epiglottis. They eventually insert along the **lateral and apical margins** of the organ. These muscles are responsible for retracting and broadening the tongue, as well as elevating the tip of the tongue. The net effect of these muscles results in **shortening** of the organ.

Another set of muscles occupy the dorsoventral plane of the tongue deep to the superior longitudinal muscles. These are the **vertical muscles** that arise from the root of the organ and genioglossus muscle and insert into the median fibrous septum, along the entire length of the organ. These muscles facilitate **flattening** and **widening** of the tongue.

Deep to the ventral muscles is the layer of **transverse muscles** of the tongue. They take a lateral route, extending from either side of the **medial lingual septum** (origin) to the **fibrous submucosa** along the lateral margins of the tongue (insertion). As these muscles contract, they cause the tongue to **narrow** and **elongate**.

Finally, the **inferior longitudinal muscles** travel above the ventral submucosa of the tongue. These fibers travel between hyoglossus and genioglossus as it arises from the **base** of the tongue and body of the **hyoid bone**. The fibers end in the **apex** of the tongue; allowing the muscle to pull the tip of the tongue inferiorly and also shortening the organ.

The intrinsic tongue muscles can operate independently, or in combination with each other to give rise to numerous shapes. This is an important feature of the tongue as it facilitates molding of the food particles into a bolus in preparation for **deglutition** and **speech**.

Extrinsic tongue muscles

While the shape of the tongue is determined by the intrinsic muscles of the tongue, movement of the organ within (and out of) the oral cavity is dependent on the extrinsic tongue muscles. There are four pairs of **extrinsic muscles**, which can be viewed as those arising from above the tongue, and those that originate from below the tongue.

Styloglossus and palatoglossus are the two muscles arising from above. **Palatoglossus** is anatomically a part of the pharyngeal group of muscles. However, its attachments to the tongue mean that it is also an extrinsic tongue muscle. It originates from the oral part of the **aponeurosis of the soft palate**. Here, and also at its insertion in the **lateral margins of tongue**, the muscle is wider than along its middle section. Its role as an extrinsic tongue muscle is to **elevate** the dorsal surface of the tongue, and (while working synergistically with the contralateral palatoglossus) to act as a **sphincter** at the oropharyngeal isthmus.

Styloglossus originates from the anterolateral surface of the **styloid process**. Not only does it contribute to the stylomandibular ligament, but it also assists in **retraction** of the tongue (moving it posterosuperiorly). It is the smallest and shortest of the three styloid muscles. At the lateral margin of the tongue, the muscle bifurcates into **longitudinal** and **oblique components**. The former pierces the tongue on the dorsolateral aspect and integrates with the inferior longitudinal muscle; while the latter crosses over and decussates with hyoglossus.

Genioglossus and hyoglossus arise from below. **Genioglossus** originates from a slender tendon that is attached to the superior genial tubercle found on the inner surface of the **symphysis menti**. This attachment prevents the tongue from falling backward and obstructing the airway when an individual is supine. The lower fibers of the muscle also have indirect attachments to the anterior part of the **body of the hyoid bone** via its slender aponeurosis. It is a triangular, midline structure that travels posterosuperiorly at which point the upper fibers of the muscle interdigitate with the intrinsic muscles, before attaching along the length of the **inferior surface of the tongue** (extending from the root to the tip).

Hyoglossus originates from the entire **greater cornu of the hyoid bone** as a slender, quadrilateral muscle. It is often accompanied by **chondroglossus** (may be considered as part of the hyoglossus), which arises from the base of the lesser cornu of the hyoid bone. Hyoglossus takes a vertical course cranially, where it pierces the inferolateral margins of the tongue and subsequently blends between the inferior longitudinal muscles and the styloglossus.

The extrinsic muscles play an important role in pressing and molding the food bolus in preparation for the initial phase of **swallowing**. Additionally, they are used to move the bolus posteriorly into the oropharyngeal inlet. Furthermore, the action of palatoglossus closes off the oropharyngeal isthmus in order to prevent food from moving cranially during swallowing. Although some of these muscles are able to act in isolation, it is the combined effect of all the intrinsic and extrinsic muscles that allows the tongue to have significant **flexibility**.

Blood supply and lymphatic drainage

Arteries

The vascular supply to the tongue muscles is provided by derivatives of the **lingual artery**. This is a branch of the external carotid artery that traverses the region between the middle pharyngeal constrictor and hyoglossus in order to access the floor of the mouth. It takes a sharp superior turn at the anterior border of hyoglossus as it travels alongside CN IX. Of note, the tongue has good collateral supply as the lingual artery also anastomosis with the contralateral vessel. The named branches of the lingual artery are as follows:

1. The **dorsal lingual arteries** are relatively small derivatives of the lingual artery that arise medial to hyoglossus. In addition to supplying the dorsal mucosa of the tongue, it also gives branches to the palatoglossus, soft palate, palatine tonsils, and epiglottis.
2. Emerging at the anterior limit of the hyoglossus, the **sublingual arteries** course between the mylohyoid and genioglossus as it travels towards the sublingual glands in the floor of the oral cavity. As it arborizes, one of its branches anastomoses with the submental branches of the facial artery, while another traverses the gingiva of the mandible to anastomose with the analogous contralateral vessel.
3. As the lingual artery terminates near the lingual frenulum on the ventral surface of the tongue, it is referred to as the **deep lingual artery**.

The lingual artery is supported by other branches of the external carotid artery. The facial artery gives off the **ascending palatine** and **tonsillar arteries** that also supply the tongue. The **ascending pharyngeal branch** of the external carotid artery also supplies the organ.

Veins

The veins of the tongue are named similarly to the arteries that they accompany. They are formed from numerous venous tributaries that eventually coalesce. As the **deep lingual vein** forms adjacent to the apex of the tongue, it courses along the ventral surface of the tongue (deep to the mucosa). As the deep lingual vein anastomosis with the **sublingual vein**, they become the **vena comitans of CN XII**. This venous network eventually drains to the **lingual vein** that later join the facial or the anterior division of the **retromandibular veins**. Here, they form the **common facial vein**, which is a tributary to the internal jugular vein. Alternatively, the venae comitantes may drain directly to the internal jugular vein.

The **dorsal lingual veins** are responsible for draining the lateral margins and dorsal surface of the tongue. They travel alongside the similarly named artery as they drain into the **internal jugular vein**

Lymphatic drainage

When discussing the lymphatic drainage of the tongue, it helps to group them according to the region of the tongue that they drain. The **marginal** and **central groups** drain the anterior parts of the tongue, while the **dorsal group** drains lymph from the posterior third of the organ. It is not uncommon to see the central area of the tongue draining to both marginal and dorsal groups of lymph vessels.

The marginal lymph vessels will carry lymph to the **submandibular nodes** or to the **jugulo-omohyoid nodes**. It is not uncommon to see lymph vessels decussating to drain to contralateral lymph nodes. The vessels from the central region may go to the **deep cervical nodes**, with a particular preference for the jugulo-omohyoid or jugulodigastric nodes. The dorsal group of vessels also pass laterally on either side to eventually join the marginal vessels in their course to the jugulo-omohyoid and jugulodigastric vessels

Innervation

The tongue has multiple sources of innervation based on its embryological origins. The nerve supply to the tongue can be grouped based as efferent fibers that carry motor impulses, general sensory that conveys touch and proprioception, and special afferent that conveys gustatory impulses.

Motor innervation

The muscles of the tongue arise from **occipital myotomes** that migrated to the floor of the pharyngeal apparatus during development. These primitive myocytes took the fibers of CN XII along with them during their journey. As a result, **CN XII** provides motor **innervation to all the muscles** of the tongue, except palatoglossus. As CN XII pierces the ventrolateral part of the pharyngeal tongue, it gives a branch to the geniohyoid muscle. Subsequently, it bifurcates into medial and lateral branches. The medial branch innervates the posterior part of the transverse and vertical muscles, as well as the medial part of the inferior longitudinal muscle, and the entire genioglossus. The lateral branch of CN XII innervates the lateral part of the inferior longitudinal, superior longitudinal, hyoglossus and styloglossus muscles.

While there is an agreement regarding the fact that the **pharyngeal plexus** brings motor fibers to the muscle, there is still some discrepancy regarding which component of the pharyngeal plexus (i.e. cranial part of accessory nerve [CN XI] or the vagus nerve [CN X]) that the fibers arise from. Some sources state that CN XI piggybacks on CN X to supply palatoglossus. However, other sources are adamant that there is no hitch-hiking, and that CN X is the nerve that supplies the palatoglossus. One thing is certain, and it's that nucleus ambiguus provides efferent fibers that innervate the skeletal muscles of the soft palate. Whether or not these fibers travel via CN X or CN XI is still uncertain.

Tactile sensory innervation

The **lingual nerve** is a branch of CN V3. It is responsible for conveying **general somatic afferent** impulses from the **anterior two-thirds** of the tongue. Additionally, it also carries **sensory information** from the oral mucosa beneath the ventral surface of the tongue as well as the gingival mucosa of the lingual side of the mandible. **General afferent** impulses from the circumvallate papillae, along with the **posterior third** of the tongue are carried by fibers of **CN IX**

Taste innervation

There are three cranial nerves responsible for conveying taste sensation from the tongue to the brain. These are CN VII, CN IX, and (to a lesser extent) CN X. The region of the tongue covered by each nerve is dependent on the proximity of the developing taste bud (and lingual papilla) to the free nerve ending. **CN VII** mitigates special sensory signals from the **anterior two-thirds** of the tongue, as well as from the inferior part of the **soft palate**.

Fibers of the **chorda tympani** travel by means of the lingual nerve to detect impulses from the **sulcal tongue**. The postsulcal tongue, circumvallate papillae, palatoglossal arches, and oropharynx are governed by **CN IX**. **CN X** only provides supply to taste buds in the extreme areas of the **pharyngeal tongue**. These impulses are conveyed by the **internal laryngeal branch** of the vagus nerve.

Clinical aspects

A particular pharyngeal arch defect, known as **Pierre Robin Syndrome**, causes glossoptosis among other symptoms. This particular defect causes the tongue to be displaced posteriorly and may cause airway obstruction or apnea.

Question 2

Write an essay on the air sinuses

The **paranasal sinuses** are **air cavities** that help circulate the air that is breathed in and out of the respiratory system. They are situated around the nasal cavity and they are all paired and sometimes symmetrical, while always being bilateral. There are four different pairs of sinuses and they are called the:

maxillary sinuses

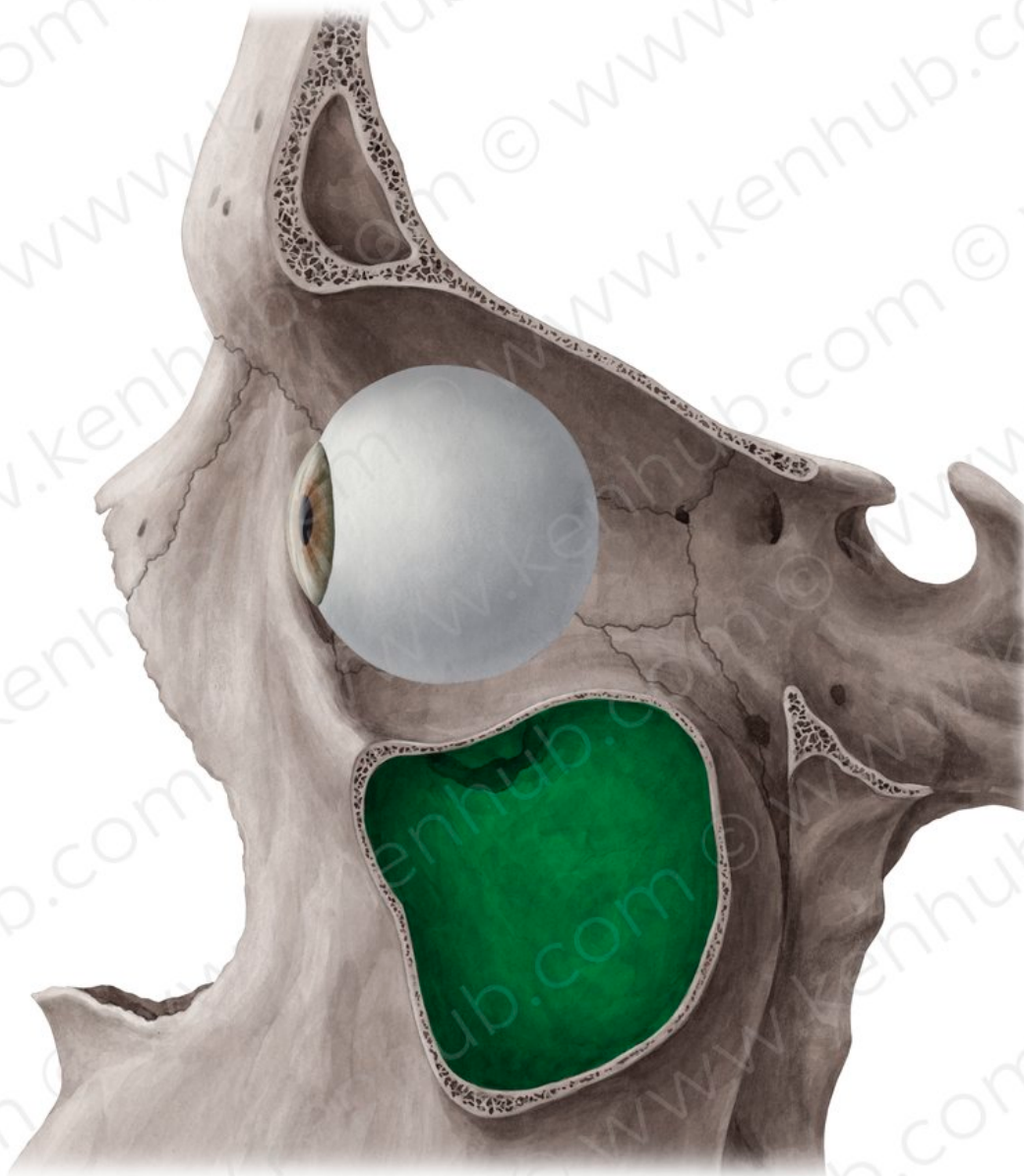
frontal sinuses

sphenoidal sinuses

ethmoidal sinuses

1. The maxillary sinuses

Anatomy



© www.kenhub.com

The maxillary sinuses are the **largest** of all the paranasal sinuses. They have thin walls which are often penetrated by the long roots of the posterior maxillary teeth. The **superior border** of this sinus is the bony orbit, the **inferior** is the maxillary alveolar bone and corresponding tooth roots, the **medial border** is made up of the nasal cavity and the **lateral** and **anterior border** are limited by the cheekbones.

Posteriorly, two anatomical spaces known as the pterygopalatine fossa and the **infratemporal fossa** exist.

Vascularization, innervation and lymphatics

The **submandibular lymph nodes** are the main destination during lymphatic drainage. The blood supply includes a contribution from the:

anterior superior alveolar artery

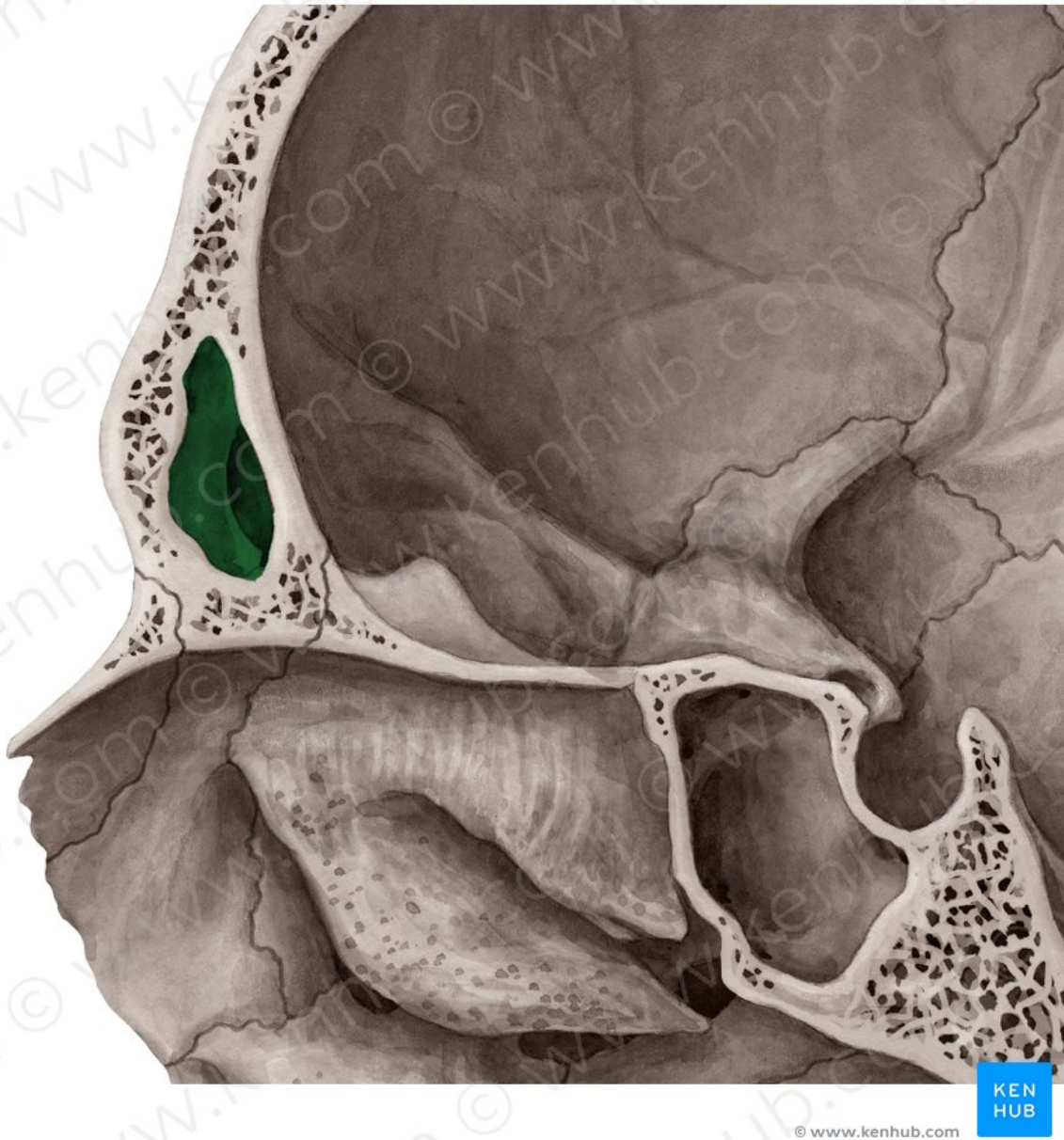
middle superior artery

posterior superior alveolar artery

Innervation occurs through nerves of the same names as the arteries

2. The frontal sinuses

Anatomy



Anteriorly, the frontal sinuses are contained by the forehead and the superciliary arches, **superiorly** and **posteriorly** by the anterior cranial fossa and **inferiorly** by the bony orbit, the anterior ethmoidal sinuses and the nasal cavity. **Medially** the sinuses face one another, separated by the midline.

This pair of sinuses are irregular in shape when compared to one another and is underdeveloped at birth. They reach their full size and shape around seven to eight years of age.

Vascularization, innervation and lymphatics

They drain primarily into the **ethmoidal infundibulum** and the corresponding lymph drainage occurs via the **submandibular lymph nodes**. It is innervated by the **ophthalmic nerve**, including the supraorbital and supratrochlear branches.

The frontal sinuses are supplied by the:

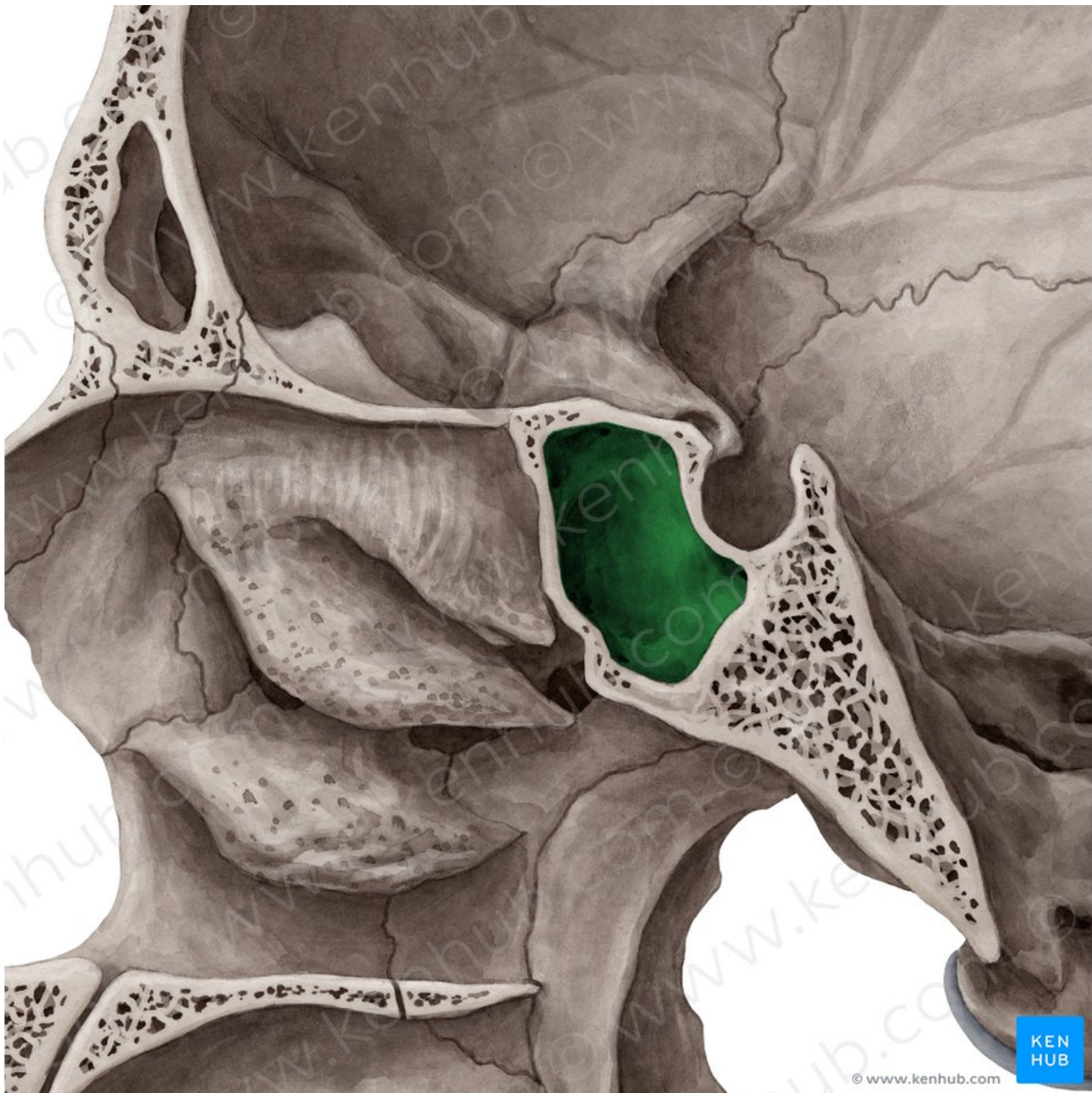
anterior ethmoidal artery

supraorbital artery

supratrochlear artery

3. The sphenoidal sinuses

Anatomy



The **most posterior** of all the sinuses in the head, the sphenoidal sinuses are large and irregular, just like their septum, which is made by the sphenoid bone. **Laterally**, a cavernous sinus exists which is part of the middle cranial fossa and also the carotid artery and cranial nerves III, IV, V/ I, V/II and VI can be found.

The **anterior wall** separates this pair of sinuses from the nasal cavity, as does the hypophyseal fossa, the pituitary gland and the optic chiasm **superiorly** and the nasopharynx and pterygoid canal **inferiorly**.

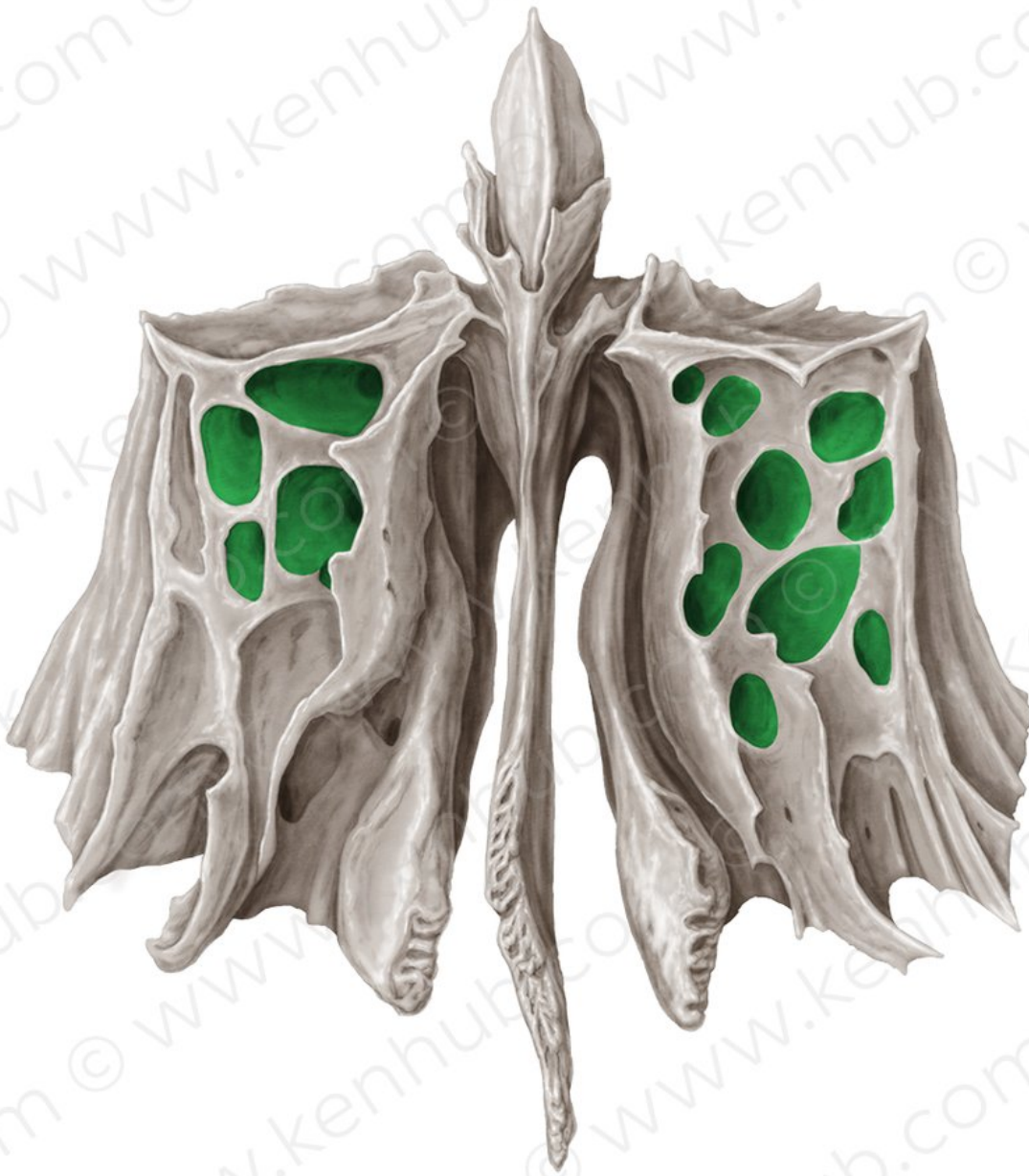Vascularization, innervation and lymphatics

The lymphatic drainage occurs in the same way as the posterior ethmoid sinus. The **posterior ethmoidal artery** and the **posterior lateral nasal branches** supply the sphenoidal sinuses.

The **posterior ethmoidal nerve** and the orbital branch of the **pterygopalatine ganglion** innervate them.

4. The ethmoidal sinuses

Anatomy



Ethmoidal cells

Superior to the ethmoidal sinus is the anterior cranial fossa and the frontal bone, **laterally** the orbit can be found, while the nasal cavity is situated **medially**. The ethmoid sinuses are unique because they are the only paranasal sinuses that are more **complex** than just a single cavity.

On each side of the midline, anywhere from three to eighteen **ethmoidal air cells** may be grouped together. These air cells are smaller individual sinuses grouped together to form one large one which encompass the anterior, middle and posterior nasal meatuses.

Vascularization, innervation and lymphatics

The anterior and middle ethmoid sinuses send their lymphatic drainage to the **submandibular lymph nodes** while the posterior ethmoid sinus sends its own to the **retropharyngeal lymph nodes**.

The **anterior** and **posterior ethmoidal arteries**, as well as the **posterior lateral nasal branches** provide an ample blood supply to this region. Meanwhile the **anterior** and **posterior ethmoidal nerves** and the **posterior lateral superior** and **inferior nasal nerves** help innervate it

Clinical aspect

Sinusitis

Sinusitis is an extremely common outpatient case which presents as an inflammation of the **epithelia** of the sinuses. The causes can be either a viral or bacterial infection, or an allergic reaction. The inflammation can be **acute** or **chronic** and the **maxillary sinuses** are the most frequently affected. Antivirals, antibiotics and antihistamines are prescribed in persistent cases.