

Name: - Adebamiro Adedoyin .F.

Matric Number: - 17/MHS01/010

ANA 301 Assignment; - Anatomy of the tongue and air sinuses.

Course Title: - Gross Anatomy of Head and Neck.

1) Anatomy of the tongue and its applied anatomy.

Under normal circumstances, the tongue is a pink, muscular organ located within the oral cavity proper. It is kept moist by the products of the major and minor salivary glands, which aids the organ as it facilitates deglutition, speech, and gustatory perception. While there is significant variability in the length of the tongue among individuals, on average, the organ is roughly 10cm long. It has three main parts:-

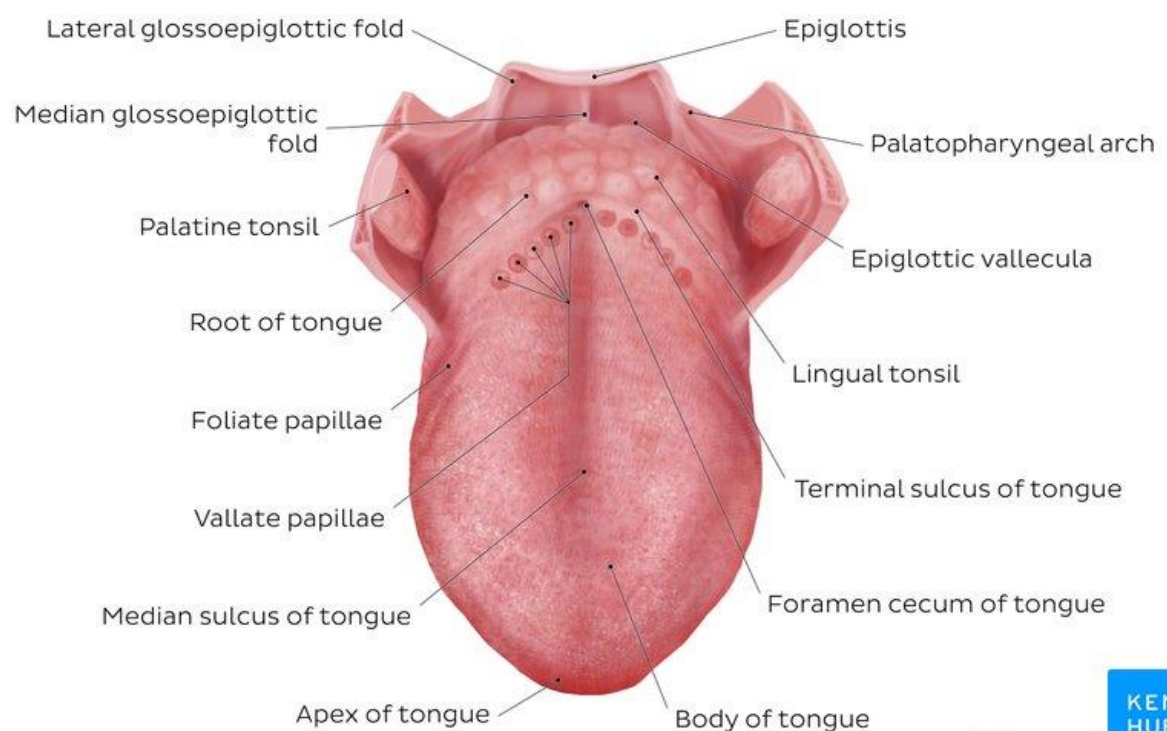
- The tip or apex of the tongue is the most anterior, and most mobile aspect of the organ.
- The tip is followed by the body of the tongue. It has a rough dorsal (superior) surface that abuts the palate and is populated with taste buds and lingual papillae, and a smooth ventral (inferior) surface that is attached to the floor of the oral cavity by the lingual frenulum.
- The base of the tongue is the most posterior part of the organ. It is populated by numerous lymphoid aggregates known as the lingual tonsils along with foliate papillae along the posterolateral surface.

There are numerous important structures surrounding the tongue. It is limited anteriorly and laterally by the upper and lower rows of teeth. Superiorly, it is bordered by the hard (anterior part) and soft (posterior part) palates. Inferiorly, the root of the tongue is continuous

with the mucosa of the floor of the oral cavity; with the sublingual salivary glands and vascular bundles being located below the mucosa of the floor of the oral cavity.

The palatoglossal and palatopharyngeal arches (along with the palatine tonsils) have lateral relations to the posterior third of the tongue. Posterior to the base of the tongue is the dorsal surface of the epiglottis and laryngeal inlet, and the posterior wall of the oropharynx. As mentioned earlier, the presulcal and postsulcal parts of the tongue differ not only by anatomical location, but also based on embryological origin, innervation, and the type of mucosa found on its surface.

Structure of the Tongue.



Anterior two thirds

The presulcal tongue includes the apex and body of the organ. It terminates at the sulcus terminalis; which can be seen extending laterally in an oblique direction from the

foramen cecum towards the palatoglossal arch. The mucosa of the dorsal surface of the oral tongue is made up of circumvallate, filiform, and fungiform papillae. There is also a longitudinal midline groove running in an anteroposterior direction from the tip of the tongue to the foramen cecum. This marks the embryological point of fusion of the lateral lingual swellings that formed the oral tongue. It also represents the location of the median lingual (fibrous) septum of the tongue that inserts in the body of the hyoid bone.

On the lateral surface of the oral tongue are foliate papillae arranged as a series of vertical folds. The ventral mucosa of the oral tongue is comparatively unremarkable. It is smooth and continuous with the mucosa of the floor of the mouth and the inferior gingiva. The lingual veins are relatively superficial and can be appreciated on either side of the lingual frenulum. Lateral to the lingual veins are pleated folds of mucosa known as the plica fimbriata. They are angled anteromedially toward the apex of the tongue.

Posterior third

The remainder of the tongue that lies posterior to the sulcus terminalis is made up by the base of the organ. It lies behind the palatoglossal folds and functions as the anterior wall of the oropharynx. Unlike the oral tongue, the pharyngeal tongue does not have any lingual papillae. Instead, its mucosa is populated by aggregates of lymphatic tissue known as the lingual tonsils. The mucosa is also continuous with the mucosa of the laterally located palatine tonsils, the lateral oropharyngeal walls, and the posterior epiglottis and glossoepiglottic folds.

Muscles of the Tongue

The tongue is chiefly a muscular organ with some amount of fatty and fibrous tissue distributed throughout its substance. All the muscles of the tongue are paired structures, with each copy being found on either side of the median fibrous septum. There are muscles that extend outside of the organ to anchor it to surrounding bony structures, known as extrinsic muscles. The other set of muscles are confined to each half of the organ and contribute to altering the shape of the organ; these are the intrinsic muscles.

a) Intrinsic tongue muscles: -

The intrinsic tongue muscles are responsible for adjusting the shape and orientation of the organ. It is made up of four paired muscles, which are discussed below in a dorsoventral manner.

The superior longitudinal muscles are made up of a thin layer of muscle fibers traveling in a mixture of oblique and longitudinal axes just deep to the superior mucosal surface of the organ. These fibers arise from the median fibrous septum as well as the fibrous layer of submucosa from the level of the epiglottis. They eventually insert along the lateral and apical margins of the organ. These muscles are responsible for retracting and broadening the tongue, as well as elevating the tip of the tongue. The net effect of these muscles results in shortening of the organ.

Another set of muscles occupy the dorsoventral plane of the tongue deep to the superior longitudinal muscles. These are the vertical muscles that arise from the root of the organ and genioglossus muscle and insert into the median fibrous septum, along the entire length of the

organ. These muscles facilitate flattening and widening of the tongue.

Deep to the ventral muscles is the layer of transverse muscles of the tongue. They take a lateral route, extending from either side of the medial lingual septum (origin) to the fibrous submucosa along the lateral margins of the tongue (insertion). As these muscles contract, they cause the tongue to narrow and elongate.

Finally, the inferior longitudinal muscles travel above the ventral submucosa of the tongue. These fibers travel between hyoglossus and genioglossus as it arises from the base of the tongue and body of the hyoid bone. The fibers end in the apex of the tongue; allowing the muscle to pull the tip of the tongue inferiorly and also shortening the organ.

The intrinsic tongue muscles can operate independently, or in combination with each other to give rise to numerous shapes. This is an important feature of the tongue as it facilitates molding of the food particles into a bolus in preparation for deglutition and speech.

b) Extrinsic tongue muscles: -

While the shape of the tongue is determined by the intrinsic muscles of the tongue, movement of the organ within (and out of) the oral cavity is dependent on the extrinsic tongue muscles. There are four pairs of extrinsic muscles, which can be viewed as those arising from above the tongue, and those that originate from below the tongue.

Styloglossus and palatoglossus are the two muscles arising from above.

Palatoglossus is anatomically a part of the pharyngeal group of muscles. However, its attachments to the tongue mean that it is also an extrinsic tongue muscle. It originates from the oral part of the aponeurosis of the soft palate. Here, and also at its insertion in the lateral margins of tongue, the muscle is wider than along its middle section. Its role as an extrinsic tongue muscle is to elevate the dorsal surface of the tongue, and (while working synergistically with the contralateral palatoglossus) to act as a sphincter at the oropharyngeal isthmus.

Styloglossus originates from the anterolateral surface of the styloid process. Not only does it contribute to the stylomandibular ligament, but it also assists in retraction of the tongue (moving it posterosuperiorly). It is the smallest and shortest of the three styloid muscles. At the lateral margin of the tongue, the muscle bifurcates into longitudinal and oblique components. The former pierces the tongue on the dorsolateral aspect and integrates with the inferior longitudinal muscle; while the latter crosses over and decussates with hyoglossus.

Genioglossus and hyoglossus arise from below.

Genioglossus originates from a slender tendon that is attached to the superior genial tubercle found on the inner surface of the symphysis menti. This attachment prevents the tongue from falling backward and obstructing the airway when an individual is supine. The lower fibers of the muscle also have indirect attachments to the anterior part of the body of the hyoid bone via its slender aponeurosis. It is a triangular, midline structure that travels posterosuperiorly at which point the upper fibers of the muscle interdigitate with the intrinsic

muscles, before attaching along the length of the inferior surface of the tongue (extending from the root to the tip).

Hyoglossus originates from the entire greater cornu of the hyoid bone as a slender, quadrilateral muscle. It is often accompanied by chondroglossus (may be considered as part of the hyoglossus), which arises from the base of the lesser cornu of the hyoid bone.

Hyoglossus takes a vertical course cranially, where it pierces the inferolateral margins of the tongue and subsequently blends between the inferior longitudinal muscles and the styloglossus.

The extrinsic muscles play an important role in pressing and molding the food bolus in preparation for the initial phase of swallowing. Additionally, they are used to move the bolus posteriorly into the oropharyngeal inlet.

Furthermore, the action of palatoglossus closes off the oropharyngeal isthmus in order to prevent food from moving cranially during swallowing. Although some of these muscles are able to act in isolation, it is the combined effect of all the intrinsic and extrinsic muscles that allows the tongue to have significant flexibility.

Blood Supply and Lymphatic Drainage

Arterial Supply

The vascular supply to the tongue muscles is provided by derivatives of the lingual artery. This is a branch of the external carotid artery that traverses the region between the middle pharyngeal constrictor and hyoglossus in order to access the floor of the mouth. It takes a sharp superior turn at the anterior border of hyoglossus as it travels alongside CN IX. Of note, the tongue has good collateral

supply as the lingual artery also anastomosis with the contralateral vessel. The named branches of the lingual artery are as follows:

The dorsal lingual arteries are relatively small derivatives of the lingual artery that arise medial to hyoglossus. In addition to supplying the dorsal mucosa of the tongue, it also gives branches to the palatoglossus, soft palate, palatine tonsils, and epiglottis.

Emerging at the anterior limit of the hyoglossus, the sublingual arteries course between the mylohyoid and genioglossus as it travels towards the sublingual glands in the floor of the oral cavity. As it arborizes, one of its branches anastomoses with the submental branches of the facial artery, while another traverses the gingiva of the mandible to anastomose with the analogous contralateral vessel.

As the lingual artery terminates near the lingual frenulum on the ventral surface of the tongue, it is referred to as the deep lingual artery.

The lingual artery is supported by other branches of the external carotid artery. The facial artery gives off the ascending palatine and tonsillar arteries that also supply the tongue. The ascending pharyngeal branch of the external carotid artery also supplies the organ.

Venous Supply

The veins of the tongue are named similarly to the arteries that they accompany. They are formed from numerous venous tributaries that eventually coalesce. As the deep lingual vein forms adjacent to the apex of the tongue, it courses along the ventral surface of the tongue (deep to the mucosa). As the deep lingual vein anastomosis with the sublingual vein, they become the

vena comitans of CN XII. This venous network eventually drains to the lingual vein that later join the facial or the anterior division of the retromandibular veins. Here, they form the common facial vein, which is a tributary to the internal jugular vein. Alternatively, the venae comitantes may drain directly to the internal jugular vein.

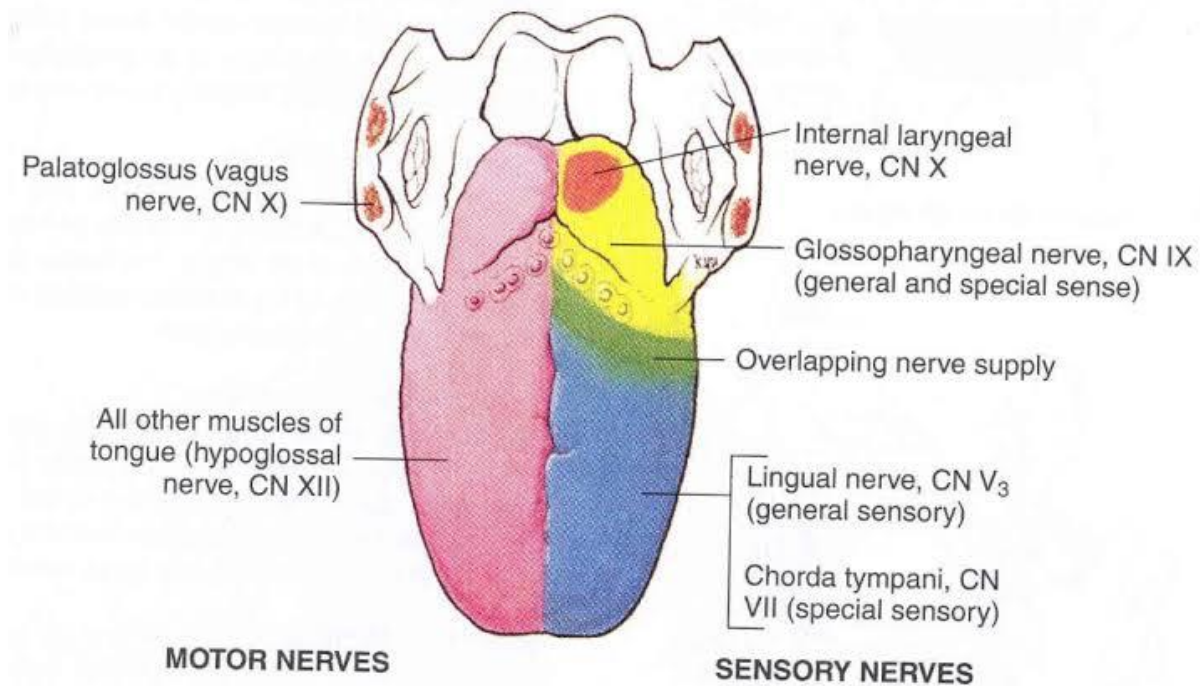
The dorsal lingual veins are responsible for draining the lateral margins and dorsal surface of the tongue. They travel alongside the similarly named artery as they drain into the internal jugular vein.

Lymphatic Drainage

When discussing the lymphatic drainage of the tongue, it helps to group them according to the region of the tongue that they drain. The marginal and central groups drain the anterior parts of the tongue, while the dorsal group drains lymph from the posterior third of the organ. It is not uncommon to see the central area of the tongue draining to both marginal and dorsal groups of lymph vessels.

The marginal lymph vessels will carry lymph to the submandibular nodes or to the jugulo-omohyoid nodes. It is not uncommon to see lymph vessels decussating to drain to contralateral lymph nodes. The vessels from the central region may go to the deep cervical nodes, with a particular preference for the jugulo-omohyoid or jugulodigastric nodes. The dorsal group of vessels also pass laterally on either side to eventually join the marginal vessels in their course to the jugulo-omohyoid and jugulodigastric vessels.

Innervation



The tongue has multiple sources of innervation based on its embryological origins. The nerve supply to the tongue can be grouped based as efferent fibers that carry motor impulses, general sensory that conveys touch and proprioception, and special afferent that conveys gustatory impulses.

Motor innervation

The muscles of the tongue arise from occipital myotomes that migrated to the floor of the pharyngeal apparatus during development. These primitive myocytes took the fibers of CN XII along with them during their journey. As a result, CN XII provides motor innervation to all the muscles of the tongue, except palatoglossus. As CN XII pierces the ventrolateral part of the pharyngeal tongue, it gives a branch to the geniohyoid muscle. Subsequently, it bifurcates into medial and lateral branches. The medial branch innervates the posterior part of the transverse and vertical muscles, as well as the

medial part of the inferior longitudinal muscle, and the entire genioglossus. The lateral branch of CN XII innervates the lateral part of the inferior longitudinal, superior longitudinal, hyoglossus and styloglossus muscles.

While there is an agreement regarding the fact that the pharyngeal plexus brings motor fibers to the muscle, there is still some discrepancy regarding which component of the pharyngeal plexus (i.e. cranial part of accessory nerve [CN XI] or the vagus nerve [CN X]) that the fibers arise from. Some sources state that CN XI piggybacks on CN X to supply palatoglossus. However, other sources are adamant that there is no hitch-hiking, and that CN X is the nerve that supplies the palatoglossus. One thing is certain, and it's that nucleus ambiguus provides efferent fibers that innervate the skeletal muscles of the soft palate. Whether or not these fibers travel via CN X or CN XI is still uncertain.

Tactile sensory innervation

The lingual nerve is a branch of CN V3. It is responsible for conveying general somatic afferent impulses from the anterior two-thirds of the tongue. Additionally, it also carries sensory information from the oral mucosa beneath the ventral surface of the tongue as well as the gingival mucosa of the lingual side of the mandible. General afferent impulses from the circumvallate papillae, along with the posterior third of the tongue are carried by fibers of CN IX.

Taste innervation

There are three cranial nerves responsible for conveying taste sensation from the tongue to the brain.

These are CN VII, CN IX, and (to a lesser extent) CN X. The region of the tongue covered by each nerve is dependent on the proximity of the developing taste bud (and lingual papilla) to the free nerve ending. CN VII mitigates special sensory signals from the anterior two-thirds of the tongue, as well as from the inferior part of the soft palate.

Fibers of the chorda tympani travel by means of the lingual nerve to detect impulses from the sulcal tongue. The postsulcal tongue, circumvallate papillae, palatoglossal arches, and oropharynx are governed by CN IX. CN X only provides supply to taste buds in the extreme areas of the pharyngeal tongue. These impulses are conveyed by the internal laryngeal branch of the vagus nerve.

Applied Anatomy of the Tongue.

- A particular pharyngeal arch defect, known as **Pierre Robin Syndrome**, causes glossoptosis among other symptoms. This particular defect causes the tongue to be displaced posteriorly and may cause airway obstruction or apnea.
- Laceration of the Tongue:-

A wound of the tongue is often caused by the patient's teeth following a blow on the chin when the tongue is partly protruded from the mouth. It can also occur when a patient accidentally bites the tongue while eating, during recovery from an anesthetic, or during an epileptic attack. Bleeding is halted by grasping the tongue between the finger and thumb posterior to the laceration, thus occluding the branches of the lingual artery.
- Lingual Carcinoma: -

A lingual carcinoma in the posterior part of the tongue metastasizes to the superior deep cervical lymph nodes on both sides, whereas a tumor in the anterior part usually does not metastasize to the inferior deep cervical lymph nodes until late in the disease. Because the nodes are closely related to the internal jugular vein, metastases from the tongue may be distributed through the submental and submandibular regions and along the internal jugular veins in the neck.

- Frenectomy: -

An overly large frenulum of the tongue (tongue-tie) interferes with tongue movements and may affect speech. In unusual cases, a frenectomy (cutting the frenulum) in infants may be necessary to free the tongue for normal movements and speech.

- Thyroglossal duct cyst: -

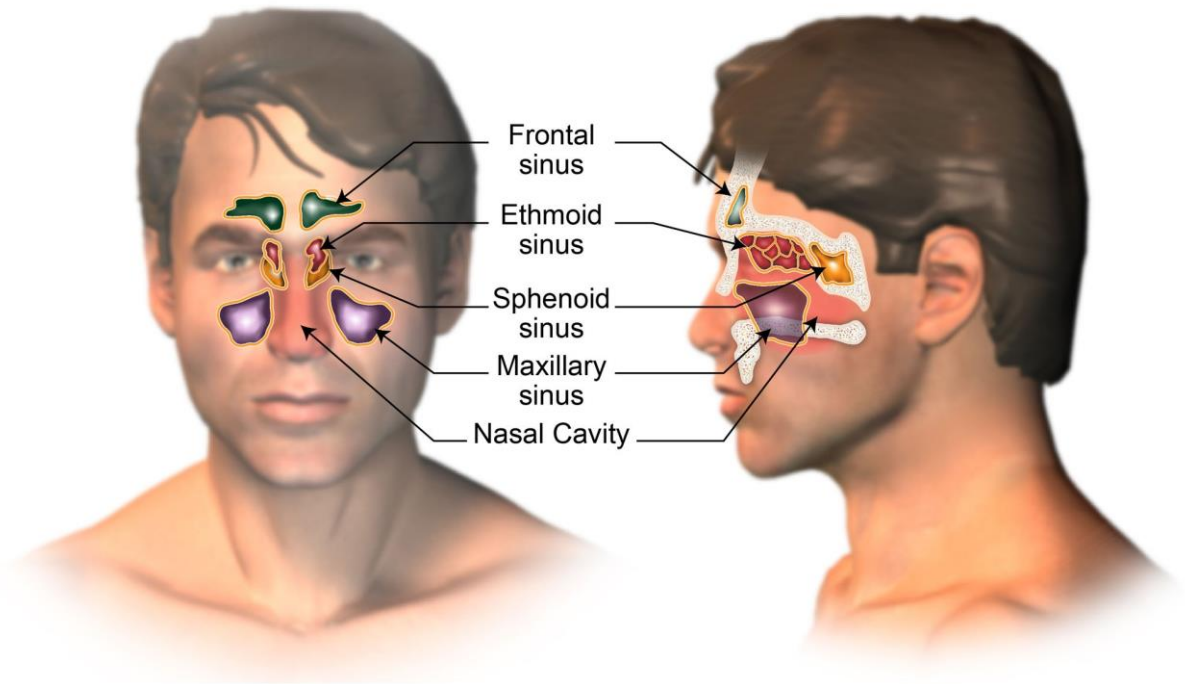
A cystic remnant of the thyroglossal duct, associated with development of the thyroid gland, may be found in the root of the tongue and be connected to a sinus that opens at the foramen cecum. Surgical excision of the cyst may be necessary. Most thyroglossal duct cysts are in the neck, close or just inferior to the body of the hyoid bone.

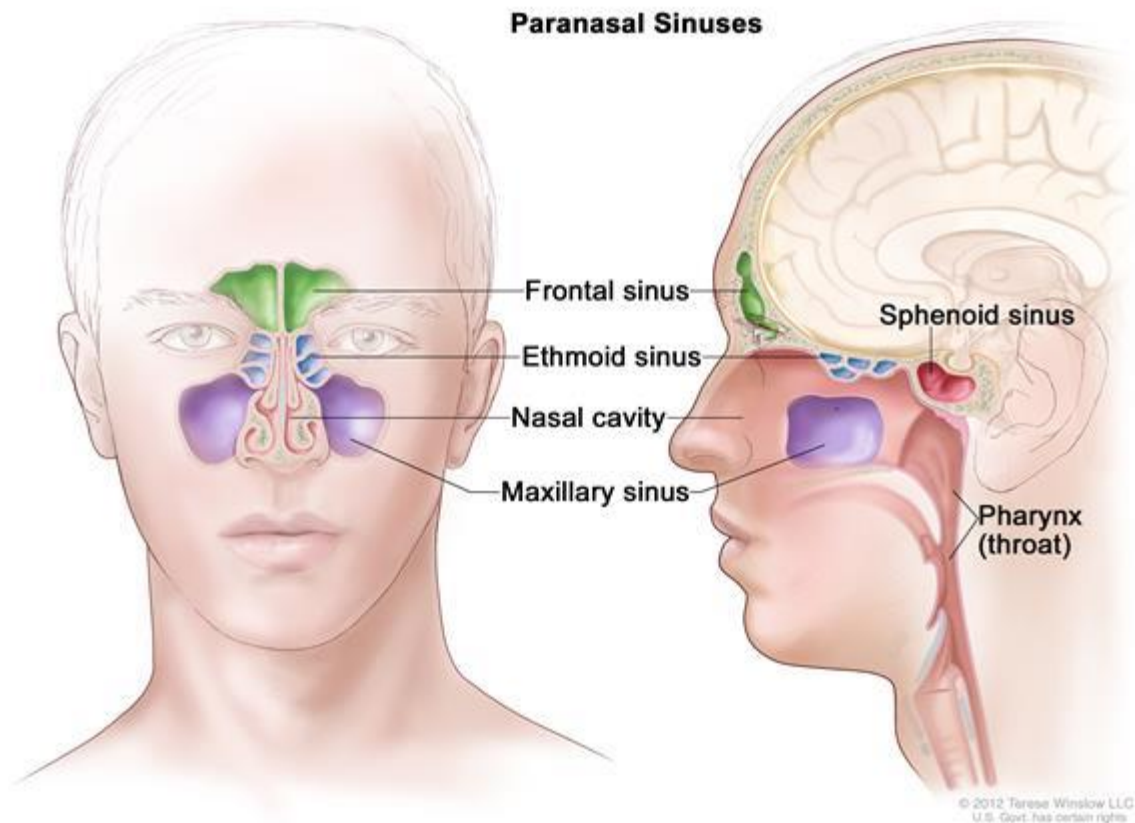
2) Essay on the air sinuses.

The paranasal sinuses are air cavities that help circulate the air that is breathed in and out of the respiratory system. They are situated around the nasal cavity and they are all paired and

sometimes symmetrical, while always being bilateral. There are four different pairs of sinuses and they are called the: -

- Maxillary sinuses
- Frontal sinuses
- Sphenoidal sinuses
- Ethmoidal sinuses





The Maxillary Sinuses: -

The maxillary sinuses are the largest of all the paranasal sinuses. They have thin walls which are often penetrated by the long roots of the posterior maxillary teeth. The superior border of this sinus is the bony orbit, the inferior is the maxillary alveolar bone and corresponding tooth roots, the medial border is made up of the nasal cavity and the lateral and anterior border are limited by the cheekbones.

Posteriorly, two anatomical spaces known as the pterygopalatine fossa and the infratemporal fossa exist.

Vascularization, innervation and lymphatics

The submandibular lymph nodes are the main destination during lymphatic drainage. The blood supply includes a contribution from the: -

- Anterior superior alveolar artery
- Middle superior artery

- Posterior superior alveolar artery

Innervation occurs through nerves of the same names as the arteries.

The Frontal Sinuses

Anteriorly, the frontal sinuses are contained by the forehead and the superciliary arches, superiorly and posteriorly by the anterior cranial fossa and inferiorly by the bony orbit, the anterior ethmoidal sinuses and the nasal cavity. Medially the sinuses face one another, separated by the midline. This pair of sinuses are irregular in shape when compared to one another and is underdeveloped at birth. They reach their full size and shape around seven to eight years of age.

Vascularization, innervation and lymphatics

They drain primarily into the ethmoidal infundibulum and the corresponding lymph drainage occurs via the submandibular lymph nodes. It is innervated by the ophthalmic nerve, including the supraorbital and supratrochlear branches. The frontal sinuses are supplied by the:

- Anterior ethmoidal artery
- Supraorbital artery
- Supratrochlear artery

The Sphenoidal Sinuses

The most posterior of all the sinuses in the head, the sphenoidal sinuses are large and irregular, just like their septum, which is made by the sphenoid bone. Laterally, a cavernous sinus exists which is part of the middle cranial fossa and also the carotid artery and cranial nerves III, IV, V/I, V/II and VI can be found.

The anterior wall separates this pair of sinuses from the nasal cavity, as does the hypophyseal fossa, the pituitary gland and the

optic chiasm superiorly and the nasopharynx and pterygoid canal inferiorly.

Vascularization, innervation and lymphatics

The lymphatic drainage occurs in the same way as the posterior ethmoid sinus. The posterior ethmoidal artery and the posterior lateral nasal branches supply the sphenoidal sinuses. The posterior ethmoidal nerve and the orbital branch of the pterygopalatine ganglion innervate them.

The Ethmoidal Sinuses

Superior to the ethmoidal sinus is the anterior cranial fossa and the frontal bone, laterally the orbit can be found, while the nasal cavity is situated medially. The ethmoid sinuses are unique because they are the only paranasal sinuses that are more complex than just a single cavity.

On each side of the midline, anywhere from three to eighteen ethmoidal air cells may be grouped together. These air cells are smaller individual sinuses grouped together to form one large one which encompass the anterior, middle and posterior nasal meatuses.

Vascularization, innervation and lymphatics

The anterior and middle ethmoid sinuses send their lymphatic drainage to the submandibular lymph nodes while the posterior ethmoid sinus sends its own to the retropharyngeal lymph nodes. The anterior and posterior ethmoidal arteries, as well as the posterior lateral nasal branches provide an ample blood supply to this region. Meanwhile the anterior and posterior ethmoidal nerves and the posterior lateral superior and inferior nasal nerves help innervate it.

Clinical Correlate

- Sinusitis: -

Sinusitis is an extremely common outpatient case which presents as an inflammation of the epithelia of the sinuses. The causes can be either a viral or bacterial infection, or an allergic reaction. The inflammation can be acute or chronic and the maxillary sinuses are the most frequently affected. Antivirals, antibiotics and antihis