

NAME: AWOJANA ANUOLUWAPO JOSEPH

MATRIC NUMBER: 17/MHS01/069

COLLEGE/DEPARTMENT: M.H.S./ M.B.B.S.

ASSIGNMENT TITLE: NOSE AND ORAL CAVITY

COURSE TITLE: GROSS ANATOMY OF HEAD AND NECK

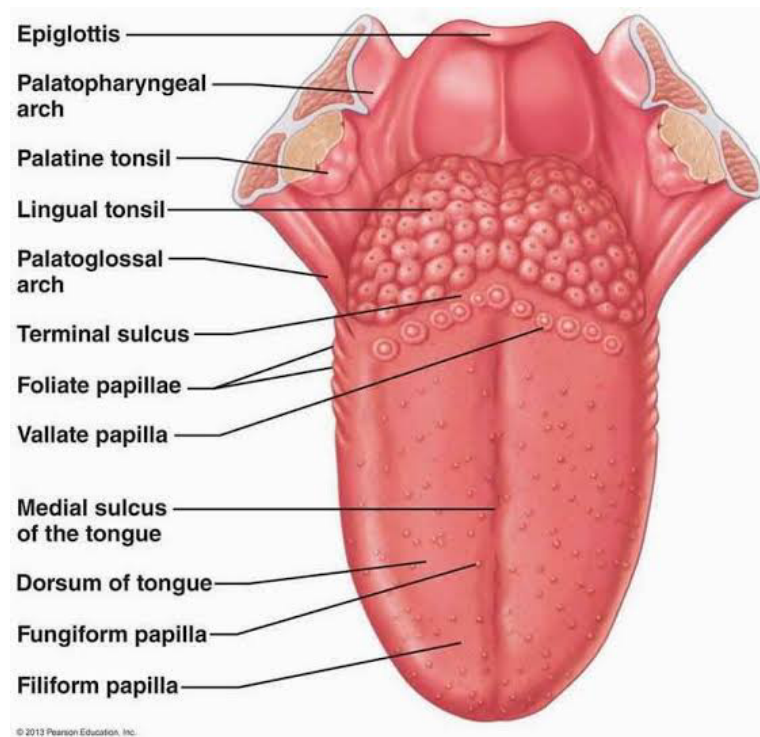
COURSE CODE: ANA 301

DATE: 02/04/2020

Question

1) Discuss the Anatomy of the tongue and comment on its applied anatomy

THE TONGUE



The tongue is a unique muscular organ located in the oral cavity that not only facilitates perception of gustatory stimuli but also plays important roles in mastication and deglutition. Additionally, the tongue is an integral component of the speech pathway, as it helps with articulation. It is kept moist by the products of the major and minor salivary glands, which aids the organ as it facilitates deglutition, speech, and gustatory perception. On average, the organ is roughly 10 cm long. It has three main parts:

- The tip or apex of the tongue is the most anterior, and most mobile aspect of the organ.
- The tip is followed by the body of the tongue. It has a rough dorsal (superior) surface that borders the palate and is populated with taste buds and lingual papillae, and a smooth ventral (inferior) surface that is attached to the floor of the oral cavity by the lingual frenulum.
- The base of the tongue is the most posterior part of the organ. It is populated by numerous lymphoid aggregates known as the lingual tonsils along with foliate papillae along the posterolateral surface.

There are numerous important structures surrounding the tongue. It is limited anteriorly and laterally by the upper and lower rows of teeth. Superiorly, it is bordered by the hard (anterior part) and soft (posterior part) palates. Inferiorly, the root of the tongue is continuous with the mucosa of the floor of the oral cavity; with the sublingual salivary glands and vascular bundles being located below the mucosa of the floor of the oral cavity. The palatoglossal and palatopharyngeal arches (along with the palatine tonsils) have lateral relations to the posterior third of the tongue. Posterior to the base of the tongue is the dorsal surface of the epiglottis and laryngeal inlet, and the posterior wall of the oropharynx. As mentioned earlier, the presulcal and postsulcal parts of the tongue differ not only by anatomical location, but also based on embryological origin, innervation, and the type of mucosa found on its surface.

Anterior two-thirds

The presulcal tongue includes the apex and body of the organ. It terminates at the sulcus terminalis; which can be seen extending laterally in an oblique direction from the foramen cecum towards the palatoglossal arch. The mucosa of the dorsal surface of the oral tongue is made up of circumvallate, filiform, and fungiform papillae. There is also a longitudinal midline groove running in an anteroposterior direction from the tip of the tongue to the foramen cecum. This marks the embryological point of fusion of the

lateral lingual swellings that formed the oral tongue. It also represents the location of the median lingual (fibrous) septum of the tongue that inserts in the body of the hyoid bone. On the lateral surface of the oral tongue are foliate papillae arranged as a series of vertical folds. The ventral mucosa of the oral tongue is comparatively unremarkable. It is smooth and continuous with the mucosa of the floor of the mouth and the inferior gingiva. The lingual veins are relatively superficial and can be appreciated on either side of the lingual frenulum. Lateral to the lingual veins are pleated folds of mucosa known as the plica fimbriata. They are angled anteromedially toward the apex of the tongue.

Posterior third

The remainder of the tongue that lies posterior to the sulcus terminalis is made up by the base of the organ. It lies behind the palatoglossal folds and functions as the anterior wall of the oropharynx. Unlike the oral tongue, the pharyngeal tongue does not have any lingual papillae. Instead, its mucosa is populated by aggregates of lymphatic tissue known as the lingual tonsils. The mucosa is also continuous with the mucosa of the laterally located palatine tonsils, the lateral oropharyngeal walls, and the posterior epiglottis and glossoepiglottic folds.

The lingual papillae

The dorsal mucosa of the oral tongue is characterized by numerous raised structures known as lingual papillae. They give the characteristic rough appearance of the dorsal surface that is not appreciated on the ventral surface of the tongue. The pharyngeal tongue also has raised dome-like structures throughout the mucosa. However, these are lymphatic aggregates (i.e. lingual tonsils) and should not be confused with papillae.

There are four types of lingual papillae found on the surface of the human tongue. These include:

-Filiform papillae are the most abundant of the four types of papillae. They are stretched, conical, grey-white papillae that are covered in a heavy coat of keratinized squamous epithelium. By making the dorsal surface of the tongue rough, these papillae provide friction to allow movement of the food bolus during chewing. It should be noted that these papillae do not possess taste buds.

-Fungiform papillae are weakly keratinized and less abundant than the filiform papillae. However, they are scattered across the entire dorsal surface of the tongue. These highly

vascular, mushroom-shaped papillae contain a few taste buds on the apical aspect.

-Foliate papillae appear as bilaterally paired, parallel, longitudinal slits on the posterolateral margin of the tongue, near the sulcus terminalis. The mucosa is non-keratinized and the papillae are populated with numerous taste buds.

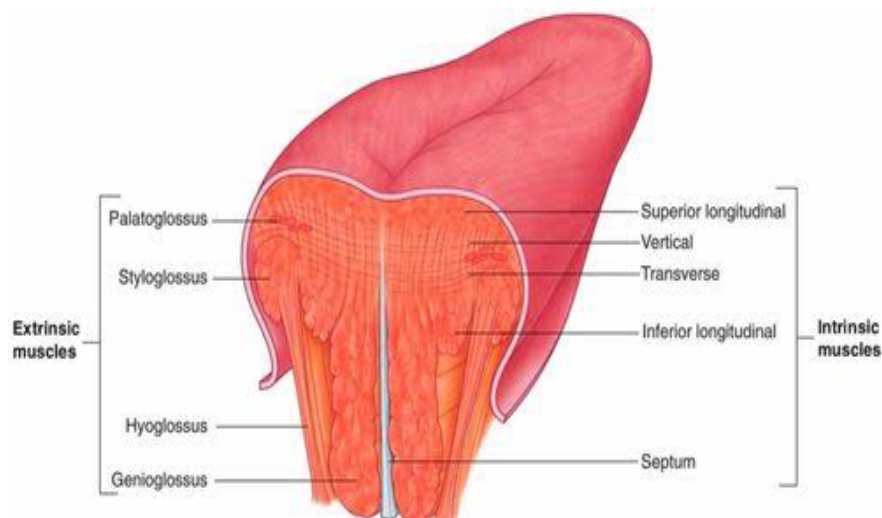
-Circumvallate (Vallate) papillae are organized linearly, as a set of four to six large papillae anterior to each limb of the sulcus terminalis (i.e. eight to twelve papillae in total). In longitudinal section, the characteristic furrow found within the papillae can be appreciated. These moats facilitate the drainage of serous salivary von Ebner glands that empty into the structure. The persistent lubrication creates a favorable environment for gustatory particles to dissolve so that they can be detected by the taste buds.

The taste buds

While taste buds are distributed throughout the entire oral cavity, they are at higher concentrations on the tongue. There are five gustatory sensations that are perceived by individuals. These are sweet, salty, sour, bitter, and umami.

Muscles

The tongue is chiefly a muscular organ with some amount of fatty and fibrous tissue distributed throughout its substance. All the muscles of the tongue are paired structures, with each copy being found on either side of the median fibrous septum. There are muscles that extend outside of the organ to anchor it to surrounding bony structures, known as extrinsic muscles. The other set of muscles are confined to each half of the organ and contribute to altering the shape of the organ; these are the intrinsic muscles



Extrinsic Muscles of the Tongue

These include:

- genioglossus
- Hyoglossus
- styloglossus
- palatoglossus

They originate outside the tongue and attach to it, they mainly move the tongue but they can alter its shape as well

Intrinsic Muscles of the Tongue

They include:

- superior longitudinal muscle
- inferior longitudinal muscle
- transverse muscle
- vertical muscles

They have their attachments entirely within the tongue and are not attached to any bone.

Blood supply and lymphatic drainage

Arteries

The vascular supply to the tongue muscles is provided by derivatives of the lingual artery. This is a branch of the external carotid artery that traverses the region between the middle pharyngeal constrictor and hyoglossus in order to access the floor of the mouth. It takes a sharp superior turn at the anterior border of hyoglossus as it travels alongside CN IX. Of note, the tongue has good collateral supply as the lingual artery also anastomosis with the contralateral vessel. The named branches of the lingual artery are as follows:

-The dorsal lingual arteries are relatively small derivatives of the lingual artery that arise medial to hyoglossus. In addition to supplying the dorsal mucosa of the tongue, it also gives branches to the palatoglossus, soft palate, palatine tonsils, and epiglottis.

-Emerging at the anterior limit of the hyoglossus, **the sublingual arteries** course between the mylohyoid and genioglossus as it travels towards the sublingual glands in the floor of the oral cavity. As it arborizes, one of its branches anastomoses with the submental branches of the facial artery, while another traverses the gingiva of the mandible to anastomose with the analogous contralateral vessel.

-As the lingual artery terminates near the lingual frenulum on the ventral surface of the tongue, it is referred to as the **deep lingual artery**.

-The lingual artery is supported by other branches of the external carotid artery. The facial artery gives off the ascending palatine and tonsillar arteries that also supply the tongue. The ascending pharyngeal branch of the external carotid artery also supplies the organ.

Veins

The veins of the tongue are named similarly to the arteries that they accompany. They are formed from numerous venous tributaries that eventually coalesce. As the deep lingual vein forms adjacent to the apex of the tongue, it courses along the ventral surface of the tongue (deep to the mucosa). As the deep lingual vein anastomosis with the sublingual vein, they become the vena comitans of CN XII. This venous network eventually drains to the lingual vein that later join the facial or the anterior division of the retromandibular veins. Here, they form the common facial vein, which is a tributary to the internal jugular vein. Alternatively, the venae comitantes may drain directly to the internal jugular vein.

The dorsal lingual veins are responsible for draining the lateral margins and dorsal surface of the tongue. They travel alongside the similarly named artery as they drain into the internal jugular vein

Lymphatic drainage

The marginal and central groups drain the anterior parts of the tongue, while the dorsal group drains lymph from the posterior third of the organ. It is not uncommon to see the central area of the tongue draining to both marginal and dorsal groups of lymph vessels.

The marginal lymph vessels will carry lymph to the submandibular nodes or to the jugulo-omohyoid nodes. It is not uncommon to see lymph vessels decussating to drain to contralateral lymph nodes. The vessels from the central region may go to the deep cervical nodes, with a particular preference for the jugulo-omohyoid or jugulodigastric

nodes. The dorsal group of vessels also pass laterally on either side to eventually join the marginal vessels in their course to the jugulo-omohyoid and jugulodigastric vessels

Innervation of the Tongue

Motor innervation

All muscles of the tongue, except the palatoglossus (actually a palatine muscle supplied by the vagus nerve(X) of the pharyngeal plexus), receive motor innervation from the hypoglossal nerve (CN XII)

Sensory innervation

The anterior two thirds of the tongue are supplied by:

- the lingual nerve (CN V3) for general sensation
- the chorda tympani, a branch of the facial nerve (CN VII) transferring nerve fibers to the lingual nerve, for taste

The posterior third of the tongue and the vallate papillae are supplied by:

- the lingual branch of the glossopharyngeal nerve (CN IX) for both general sensation and taste
- Another contribution is made by the internal laryngeal branch of the vagus (CN X) for general sensation and taste

Hence CN VII, CN IX, and CN X provide nerve fibers for taste; those from CN VII are ultimately conveyed by CN V3

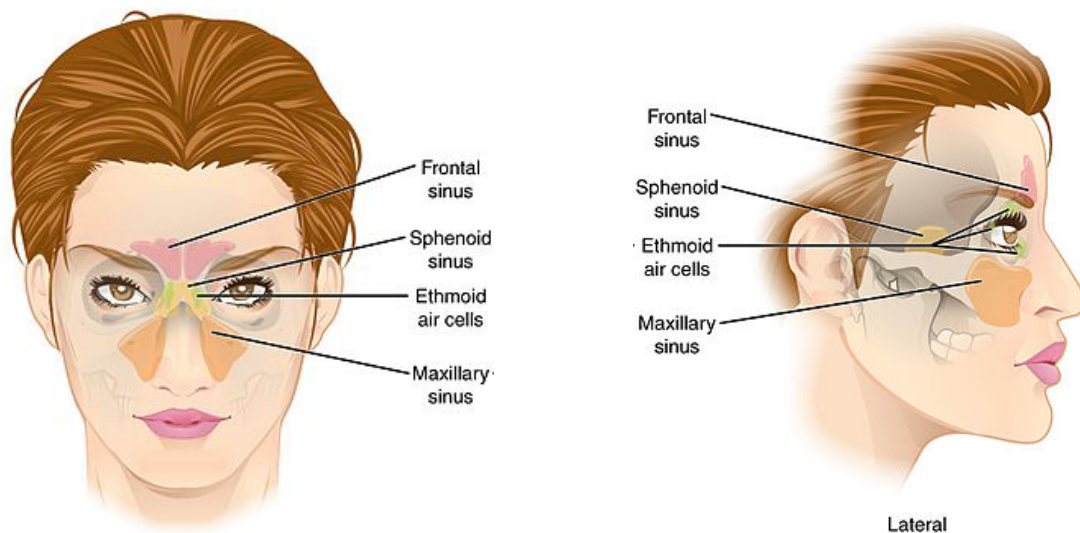
Clinical anatomy

Thrush (candidiasis): Candida albicans (a yeast) grows over the surface of the mouth and tongue. Thrush can occur in almost anyone, but it occurs more often in people taking steroids or with suppressed immune systems, the very young, and the elderly.

Oral cancer: A growth or ulcer appears on the tongue and grows steadily. Oral cancer is more common in people who smoke and/or drink alcohol heavily.

Macroglossia (big tongue): This can be broken down into various categories based on the cause. These include congenital, inflammatory, traumatic, cancerous, and metabolic causes. Thyroid disease, lymphangiomas, and congenital abnormalities are among some of the causes of an enlarged tongue.

2) write an essay on the air sinuses



AIR SINUSES

The paranasal sinuses are air cavities that help circulate the air that is breathed in and out of the respiratory system. They are situated around the nasal cavity and they are all paired and sometimes symmetrical, while always being bilateral. They have various functions, including lightening the weight of the head, humidifying and heating inhaled air, increasing the resonance of speech, and serving as a crumple zone to protect vital structures in the event of facial trauma. Sinuses are formed in childhood by the nasal cavity eroding into surrounding bone. As they are outgrowths of the nasal cavity, they all drain back into it – openings to the paranasal sinuses are found on the roof and lateral walls of the nasal cavity. The inner surface is lined by a respiratory mucosa. There are four different pairs of sinuses and they are called the:

-maxillary sinuses

-frontal sinuses

-sphenoidal sinuses

-ethmoidal sinuses

-THE MAXILLARY SINUSES: The maxillary sinuses are the largest of all the paranasal sinuses. They have thin walls which are often penetrated by the long roots of the posterior maxillary teeth. The superior border of this sinus is the bony orbit, the inferior is the maxillary alveolar bone and corresponding tooth roots, the medial border is made up of the nasal cavity and the lateral and anterior border are limited by the cheekbones. Posteriorly, two anatomical spaces known as the pterygopalatine fossa and the infratemporal fossa exist.

Vascularization, innervation and lymphatics

The submandibular lymph nodes are the main destination during lymphatic drainage. The blood supply includes a contribution from the:

-anterior superior alveolar artery

-middle superior alveolar artery

-posterior superior alveolar artery

Innervation occurs through nerves of the same names as the arteries.

-THE FRONTAL SINUSES: Anteriorly, the frontal sinuses are contained by the forehead and the superciliary arches, superiorly and posteriorly by the anterior cranial fossa and inferiorly by the bony orbit, the anterior ethmoidal sinuses and the nasal cavity. Medially the sinuses face one another, separated by the midline. This pair of sinuses are irregular in shape when compared to one another and is underdeveloped at birth. They reach their full size and shape around seven to eight years of age.

Vascularization, innervation and lymphatics

They drain primarily into the ethmoidal infundibulum and the corresponding lymph drainage occurs via the submandibular lymph nodes. It is innervated by the ophthalmic nerve, including the supraorbital and supratrochlear branches.

The frontal sinuses are supplied by the:

-anterior ethmoidal artery

-supraorbital artery

-supratrochlear artery

-THE SPHENOIDAL SINUSES: The most posterior of all the sinuses in the head, the sphenoidal sinuses are large and irregular, just like their septum, which is made by the sphenoid bone. Laterally, a cavernous sinus exists which is part of the middle cranial fossa and also the carotid artery and cranial nerves III, IV, V/I, V/II and VI can be found. The anterior wall separates this pair of sinuses from the nasal cavity, as does the hypophyseal fossa, the pituitary gland and the optic chiasm superiorly and the nasopharynx and pterygoid canal inferiorly.

Vascularization, innervation and lymphatics

The lymphatic drainage occurs in the same way as the posterior ethmoid sinus(i.e. retropharyngeal lymph nodes). The posterior ethmoidal artery and the posterior lateral nasal branches supply the sphenoidal sinuses. The posterior ethmoidal nerve and the orbital branch of the pterygopalatine ganglion innervate them.

-THE ETHMOIDAL SINUSES: Superior to the ethmoidal sinus is the anterior cranial fossa and the frontal bone, laterally the orbit can be found, while the nasal cavity is situated medially. The ethmoid sinuses are unique because they are the only paranasal sinuses that are more complex than just a single cavity. On each side of the midline, anywhere from three to eighteen ethmoidal air cells may be grouped together. These air cells are smaller individual sinuses grouped together to form a large one which encompass the anterior, middle and posterior nasal meatuses.

Vascularization, innervation and lymphatics

The anterior and middle ethmoid sinuses send their lymphatic drainage to the submandibular lymph nodes while the posterior ethmoid sinus sends its own to the retropharyngeal lymph nodes.

The anterior and posterior ethmoidal arteries, as well as the posterior lateral nasal branches provide an ample blood supply to this region. Meanwhile the anterior and posterior ethmoidal nerves and the posterior lateral superior and inferior nasal nerves help innervate it.

CLINICAL CORRELATES

-Acute sinusitis (sinus infection): Viruses, bacteria, or fungi infect the sinus cavity, causing inflammation. More mucus; nasal congestion; discomfort in the cheeks,

forehead, or around the eyes; and headaches are common symptoms.

-Chronic sinusitis (or chronic rhinosinusitis): More than just a series of infections, chronic sinusitis is a persistent process of inflammation of the sinuses.