

NAME: AWOSAN SAMUEL OLUWAGBENGA

MATRIC NO: 17/MHS01/071

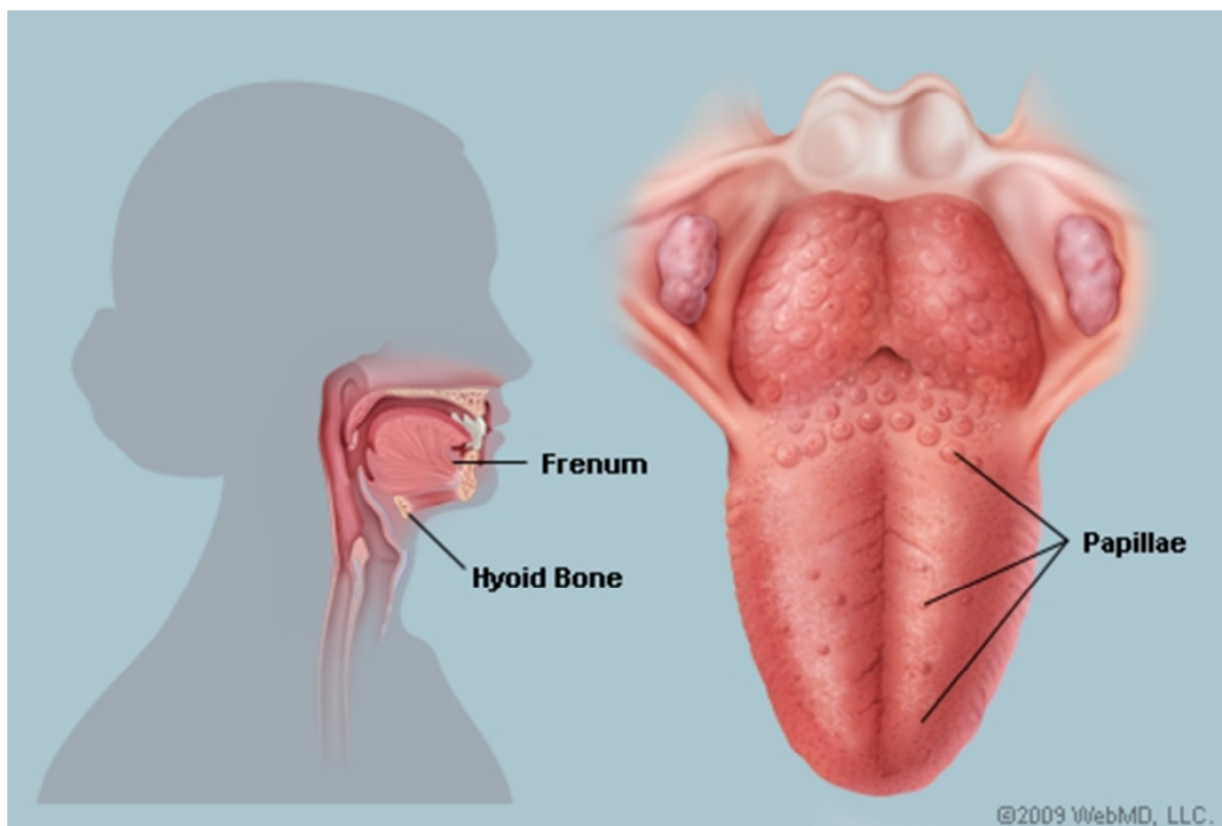
DEPARTMENT: MEDICINE AND SURGERY

GROSS ANATOMY OF HEAD AND NECK ASSIGNMENT

1. Discuss the anatomy of the tongue and comment on its applied anatomy

Anatomy

The tongue is a mass of muscle that can be divided into different parts based on its landmarks. This differentiation is helpful to connect its structure to specific unique functions. The bumps on the tongue are called papillae (from a Latin root meaning “nipple”) and these vary in shape and location and are associated with taste buds. The muscles within and surrounding the tongue control its movement.



Gross Parts

When looking at the tongue from its surface, it is possible to divide the tongue into unique parts. This is important because different parts of the tongue may be supported by distinct nerves and blood vessels.

One of the most important landmarks of the tongue is the central or terminal sulcus, lying about two-thirds from the tongue's tip. The tongue may be further divided into right and left halves by the midline groove and just beneath the groove's surface lies the fibrous lingual septum. The underside of the tongue is covered with a thin, transparent mucous membrane through which one can see the underlying veins.

The lingual frenulum is a large midline fold of mucosa that passes from the tongue side of the gums (or gingiva) to the lower surface of the tongue. The frenulum connects the tongue to the floor of the mouth while allowing the tip to move freely. It is notable that the submandibular salivary gland has a duct that opens beneath the tongue, passing saliva into the mouth here.

Consider these general descriptions of the gross parts of the tongue:

- **Root:** This is most often defined as the back third of the tongue. It sits low in the mouth and near the throat, and it is relatively fixed in place. It is attached to the hyoid bone and mandible (lower jaw). It is close in proximity to two muscles: the geniohyoid and mylohyoid muscles.
- **Body:** The rest of the tongue, notably the forward two-thirds that lie in front of the sulcus. It is extremely mobile and serves multiple functions.
- **Apex:** This is the tip of the tongue, a pointed portion most forward in the mouth. It is also extremely mobile.
- **Dorsum:** This is the curved upper surface towards the back. It has a V-shaped groove on it called the terminal sulcus.
- **Inferior Surface:** Underneath the tongue lies this last feature, important for the ability to visualize veins that allow the rapid absorption of specific medications.

Papillae Types

The more forward surface of the tongue is covered in numerous small bumps called papillae. These may have different shapes, sizes, and functions. Many are associated with taste buds, but some may have other purposes. The back of the tongue has no papillae, but underlying lymphatic tissue may give it an irregular, cobblestone appearance. Consider these general findings about papillae:

- **Vallate papillae:** These large, flat-topped bumps lie just in front of the terminal sulcus, located about two-thirds back on the surface of the tongue. They are surrounded by deep trenches—into which ducts open from fluid-producing glands—and their walls are covered in taste buds.

- **Folate papillae:** Though poorly developed in humans, these small folds of the mucosa surface of the tongue are found to the sides. They also have taste receptors located in taste buds.
- **Filiform papillae:** Lying in V-shape rows parallel to the terminal sulcus, these bumps are elongated and numerous. They contain nerve endings that are sensitive to touch. Appearing scaly, threadlike, and pinkish-grey in color, they can make the tongues of some animals (such as cats) especially rough. At the tongue's tip, these papillae sit more cross-wise (arranged transversely).
- **Fungiform papillae:** Scattered among the filiform papillae are these oddly mushroom-shaped spots that may be pink or red in coloration. They are most commonly found along the tip or sides of the tongue. Many contain receptors for taste within taste buds.

Muscles

The tongue may seem like one big muscular mass. It is actually composed of many interlaced muscles, some within what would be recognized as the tongue itself and others that are nearby and control its complex movements. These various muscles are grouped as intrinsic muscles (those entirely within the tongue that affect shape) and extrinsic muscles (those that originate outside the tongue, attach to it and surrounding bones, and affect its position).

The muscles of the tongue, with main actions as noted, include intrinsic muscles and extrinsic muscles.

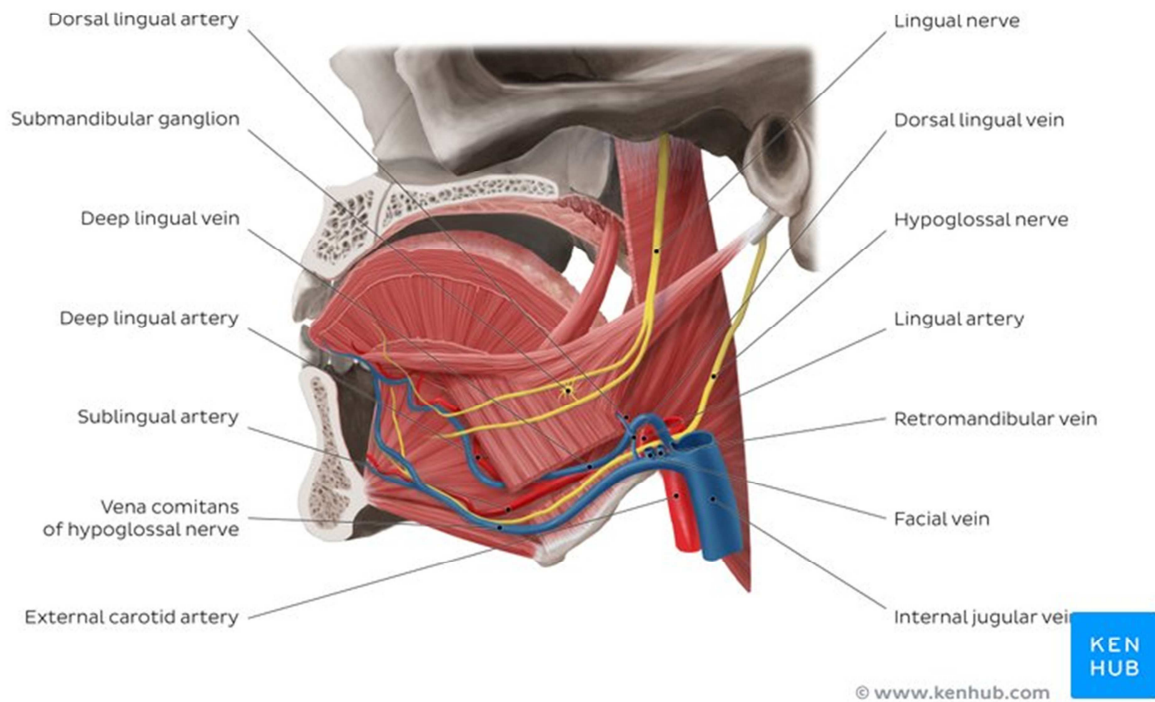
Intrinsic muscles:

- **Superior longitudinal:** Curls the tip and sides of the tongue upward and shortens the tongue.
- **Inferior longitudinal:** Curls the tip of the tongue downward and shortens the tongue.
- **Transverse:** Narrows and elongates the tongue, increasing its height and causing it to stick out (protrude).
- **Vertical:** Flattens and broadens the tongue within the mouth, causing it to protrude or push against the front teeth.

Extrinsic muscles:

- **Genioglossus:** A large fan-shaped muscle, it contributes most of the bulk to the tongue. It lowers the tongue and may pull it forward to stick out or even to wag it back and forth.
- **Hyoglossus:** A thin, four-sided muscle that lowers the tongue and pulls it back into the mouth.
- **Styloglossus:** Another small, short muscle with fibers that interdigitate with the hyoglossus muscle. It can retract the tongue and draw it up to create a trough for swallowing a bolus of food.

- **Palatoglossus:** In fact, more part of the soft palate than the tongue proper, it works to elevate the back portion of the tongue.



Nerves

All the muscles of the tongue are innervated by the hypoglossal nerve (also known as cranial nerve XII) with the exception of the palatoglossus muscle that is innervated by a branch of the pharyngeal plexus. Sensation, including touch and temperature, of the anterior two-thirds of the tongue's surface, is supplied by the lingual nerve (a branch from the trigeminal nerve). Taste is a special sensation and it comes from the chorda tympani nerve, branching from the facial nerve. The back third of the tongue receives its general and special sensation innervation from a branch of the glossopharyngeal nerve. Just forward of the epiglottis is a small patch of the tongue that receives its special sensation from the internal laryngeal nerve, a branch of the vagus nerve.

Blood Supply

Without going into excessive detail, the arteries of the tongue derive from the lingual artery, which arises from the external carotid artery. The venous drainage includes the dorsal lingual vein and deep lingual veins, emptying to the internal jugular vein. The veins under the tongue

may be enlarged and tortuous (varicose) in older people, but they do not bleed and this change has no clinical significance.

Function

The tongue is a mass of muscles covered by a mucous membrane that is important for taste sensation. Beyond its obvious role in eating—manipulating food into a bolus that can be safely passed into the throat with swallowing—it also has a vital contribution to speech and may even affect breathing, especially in sleep.

Eating

Consider how the tongue helps a person to eat food and swallow liquids. After the teeth have taken a bite with the help of the powerful muscles of the jaw, this food must be broken down into smaller pieces before it can be safely swallowed. The tongue actively moves the food within the mouth, positioning it for further degradation by the teeth. The food is mixed with saliva, ultimately becoming a manageable portion called a bolus that may be moved into the pharynx before being swallowed and passing via the esophagus into the stomach. The tongue may also help with oral cleansing, keeping food from prolonged contact with the teeth.

The tongue helps to identify what might be palatable with the sense of taste as detected by the taste buds. The basic taste sensations include:

- Sweet
- Salty
- Sour
- Bitter
- Savory (umami)

Although different regions of the tongue may be more sensitive to specific tastes, it is not as regionally distinct as was previously believed.

Speech

The tongue is also the main contributor to speech. It is not possible to form words and speak without the proper positioning of the tongue. This is dependent on the intrinsic and extrinsic muscles noted above that alter the shape and position of the tongue. This helps to articulate sounds appropriately and dysfunction of the tongue may lead to a serious speech impediment.

Breathing

If the tongue sits too far back within the throat, it may affect breathing. This is more likely to occur when mouth breathing is present. With normal nasal breathing, the mouth is kept closed, and the lower jaw will be held in a more forward position as the teeth come together. This

reduces the potential for the tongue to obstruct the airway. In sleep, the shift of the tongue that happens with mouth breathing may cause problems including snoring and obstructive sleepapnea. Weight gain may increase the size of the tongue and make this worse.¹

Other Roles

The tongue has several other important roles. It may protect the body with a gag reflex, preventing unpalatable and even poisonous substances from being consumed. If the posterior part of the tongue is touched, there may be a strong muscular contraction of the throat, closing it off.

In addition, the tongue allows a path of rapid absorption of medications. Specifically, nitroglycerin is used to dilate the heart's blood vessels when severe chest pain is occurring. With a pill or spray applied under the tongue, the medication quickly dissolves and enters the veins there in less than 1 minute.²

Clinical Anatomy

There are a handful of conditions that may be associated with the tongue, often impacting the ability to swallow or speak normally. Some are present from birth, and others may develop from an infection or exposure to cancer-causing substances. Consider these associated conditions that affect the tongue:

Ankyloglossia

As noted above, the lingual frenulum (from the Latin word meaning "bridle") is a small fold of mucous membrane that connects the middle of the lower surface of the tongue to the floor of the mouth. If it is too short, often from birth, the tongue may be abnormally retracted into the lower jaw. This lower position leads to a condition that is colloquially known as being "tongue tied." This may be rarely checked (or simply ignored), especially if it is at the back of the tongue, and often goes untreated. It may be recognized with early infancy swallowing problems and speech impairment at school age as the short frenulum may interfere with tongue movements and function. Clipping the frenulum is a simple surgery and this frenulectomy may be necessary for infants to free the tongue for normal speech development.

Genioglossus muscle paralysis

When this muscle becomes paralyzed, the tongue falls backward, potentially obstructing the airway and increasing the risk of suffocation. Total relaxation of the tongue occurs during general anesthesia. As such, this shift of the tongue must be prevented to avoid blocking the airway. This is usually accomplished by inserting a temporary breathing tube during surgery.

Hypoglossal nerve injury

Trauma to the lower jaw (mandible) may cause a fracture that injures the hypoglossal nerve, resulting in paralysis and eventual shrinking of one side of the tongue. After the injury, the tongue deviates to the paralyzed side when protruded.

Lingual carcinoma

Cancer, or carcinoma, may affect the tongue. This is more likely due to infections from human papillomavirus (HPV) or from the use of tobacco, including chewing or smoking.³ The back of the tongue has lymphatic drainage that may cause aggressive cancers to metastasize to the superior deep cervical lymph nodes on both sides of the neck. Cancers of the tongue may require surgical treatment, radiation therapy, and even chemotherapy if metastatic.

Thyroglossal duct cyst

Rarely, there can be a cystic remnant of the thyroglossal duct found within the root of the tongue. Most of these cysts lie close to the body of the hyoid bone, producing a painless swelling of the neck at the midline. It may connect with a fistula to the skin's surface, leading to a non-healing sore (called a thyroglossal fistula) at the neck. Surgery may be required for the resolution of the problem.

Aberrant thyroid gland

The thyroid gland typically descends within the embryo along the thyroglossal duct. In some cases, remnants of the thyroid gland may remain behind. These may be found in the root of the tongue or even in the neck. In some cases, it may be treated with radioactive iodine and long-term thyroid replacement for post-surgical hypothyroidism is necessary.

Other conditions

There are a few other conditions that may be associated with the tongue, such as:

- **Candidiasis**: A yeast infection commonly known as thrush is caused by *Candida albicans* that may cause a white-colored plaque on the mucosa lining the tongue and mouth. It occurs more among the immune-suppressed, especially among the young and old.
- **Hairy tongue syndrome**: The tongue may appear white or black due to overgrowth of the papillae on the surface of the tongue. A thorough scraping may clear off the debris and resolve the unpleasant appearance and associated smell.
- **Macroglossia**: Literally a big tongue, this condition may affect the ability to swallow or breathe normally. It may occur in the setting of Down syndrome, weight gain, or hypothyroidism.
- **Geographic tongue**: A patchy appearance on the surface of the tongue with ridges and colored spots that migrate over time. Though harmless, it may initially seem concerning.

- **Burning mouth syndrome**: Like it sounds, the symptoms can be unpleasant and causes may be occasionally serious.
- **Sleep apnea**: The tongue size and position may increase the risk for sleep apnea due to obstruction of airflow within the throat.¹

If concerned about a condition affecting the tongue, start by speaking with either a primary care provider, dentist, or relevant medical specialist. In some cases, further testing may be necessary to assess the condition.

Tests

As a general rule, the tongue does not require much testing to assess its health and function. Beyond a visual assessment by a physician or dentist, further evaluation may require seeing a specialist. This may be an ear, nose, and throat (ENT) specialist, a neurologist, or even a speech-language pathologist. If indicated, testing may include:

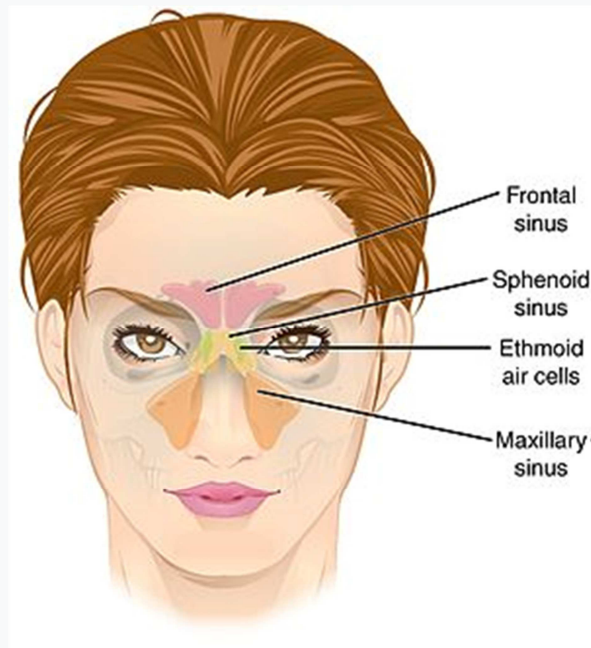
- Computerized tomography (CT) scan
- Magnetic resonance imaging (MRI) scan
- Biopsy
- Flavor discrimination test

Treatments may depend on the underlying nature of any abnormalities identified. Optimization of the function of the tongue may require surgery, specialized exercises (including [myofunctionaltherapy](#)), or other inventions.

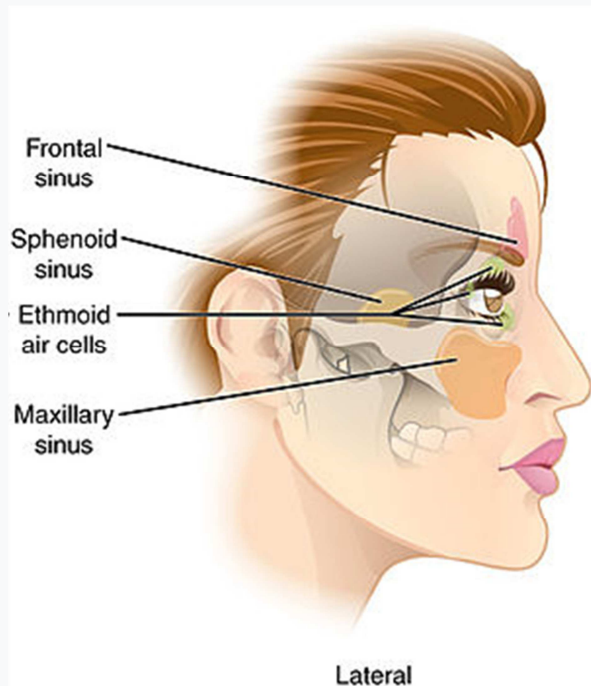
2. Write an essay on the air sinuses

Paranasal sinuses



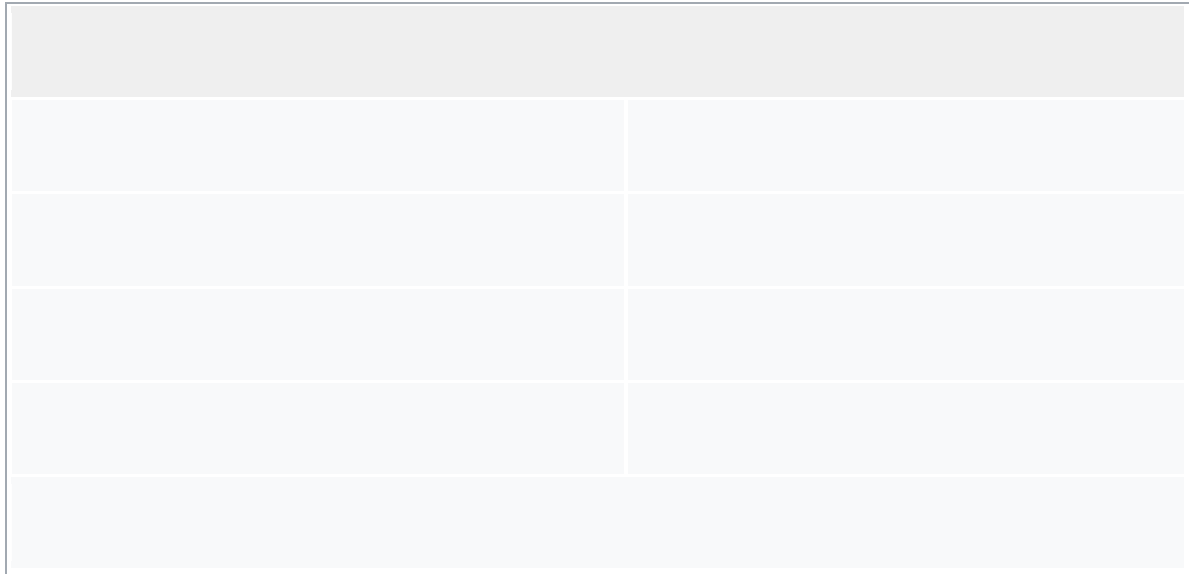


Paranasal sinuses seen in a frontal view



Lateral projection of the paranasal sinuses

Details



Paranasal sinuses are a group of four paired air-filled spaces that surround the nasal cavity. The maxillary sinuses are located under the eyes; the frontal sinuses are above the eyes; the ethmoidal sinuses are between the eyes and the sphenoidal sinuses are behind the eyes. The sinuses are named for the facial bones in which they are located.

Structure

Humans possess four paired paranasal sinuses, divided into subgroups that are named according to the bones within which the sinuses lie:

- The maxillary sinuses, the largest of the paranasal sinuses, are under the eyes, in the maxillary bones (open in the back of the semilunar hiatus of the nose). They are innervated by the trigeminal nerve (CN Vb)
- The frontal sinuses, superior to the eyes, in the frontal bone, which forms the hard part of the forehead. They are also innervated by the trigeminal nerve (CN Va).
- The ethmoidal sinuses, which are formed from several discrete air cells within the ethmoid bone between the nose and the eyes. They are innervated by the ethmoidal nerves, which branch from the nasociliary nerve of the trigeminal nerve (CN Va).
- The sphenoidal sinuses, in the sphenoid bone. They are innervated by the trigeminal nerve (CN Va & Vb).

The paranasal air sinuses are lined with respiratory epithelium (ciliated pseudostratified columnar epithelium).

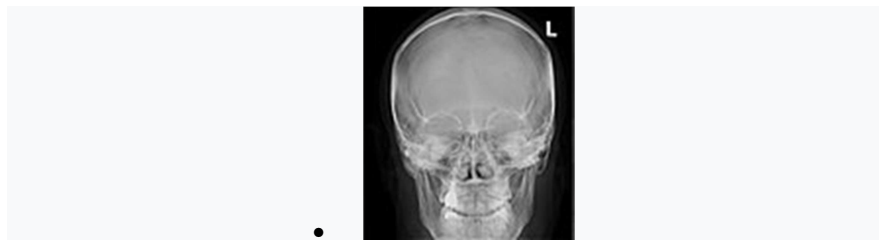
Development

Paranasal sinuses form developmentally through excavation of bone by air-filled sacs (pneumatic diverticula) from the nasal cavity. This process begins prenatally (intrauterine life), and it continues through the course of an organism's lifetime.

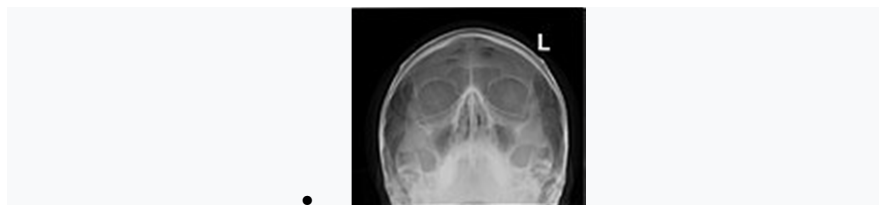The results of experimental studies suggest that the natural ventilation rate of a sinus with a single sinus ostium (opening) is extremely slow. Such limited ventilation may be protective for the sinus, as it would help prevent drying of its mucosal surface and maintain a near-sterile environment with high carbon dioxide concentrations and minimal pathogen access. Thus composition of gas content in the maxillary sinus is similar to venous blood, with high carbon dioxide and lower oxygen levels compared to breathing air.

At birth only the maxillary sinus and the ethmoid sinus are developed but not yet pneumatized; only by the age of seven they are fully aerated. The sphenoid sinus appears at the age of three, and the frontal sinuses first appear at the age of six, and fully develop during adulthood.

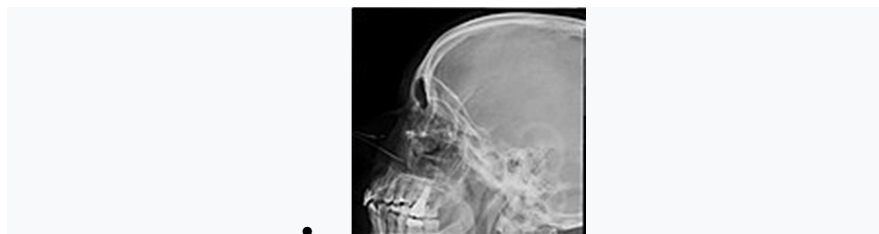X-ray images and illustrations



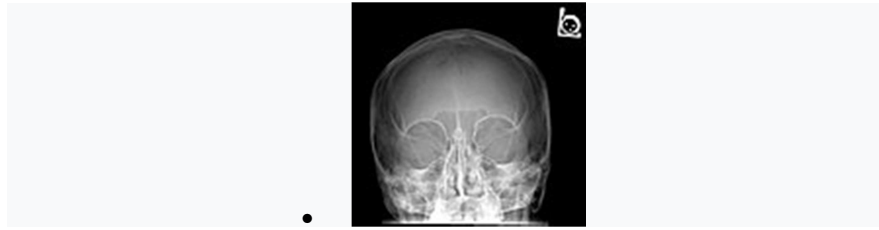
Paranasal sinuses radiograph (occipitofrontal)



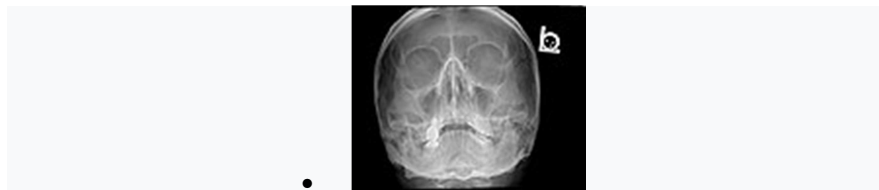
Paranasal sinuses radiograph (occipitomental)



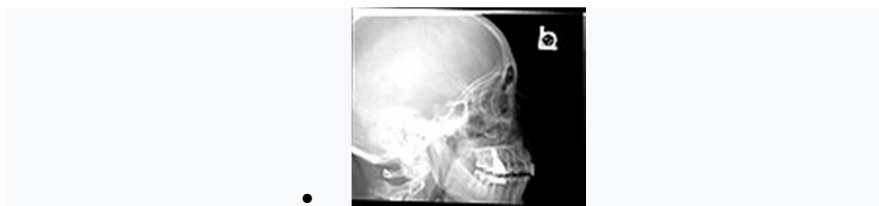Paranasal sinuses radiograph (lateral)



Paranasal sinuses radiograph (occipitofrontal)



Paranasal sinuses radiograph (occipitomental)



Paranasal sinuses radiograph (lateral)



3D cast of maxillary, frontal, ethmoid and sphenoid sinuses, nasal cavity and hypopharynx.

Clinical significance

Inflammation

The paranasal sinuses are joined to the nasal cavity via small orifices called ostia. These become blocked easily by allergic inflammation, or by swelling in the nasal lining that occurs with a cold. If this happens, normal drainage of mucus within the sinuses is disrupted, and sinusitis may occur. Because the maxillary posterior teeth are close to the maxillary sinus, this can also cause clinical problems if any disease processes are present, such as an infection in any of these teeth. These clinical problems can include

secondary sinusitis, the inflammation of the sinuses from another source such as an infection of the adjacent teeth.

These conditions may be treated with drugs such as decongestants, which cause vasoconstriction in the sinuses; reducing inflammation; by traditional techniques of nasal irrigation; or by corticosteroid.

Cancer

Malignancies of the paranasal sinuses comprise approximately 0.2% of all malignancies. About 80% of these malignancies arise in the maxillary sinus. Men are much more often affected than women. They most often occur in the age group between 40 and 70 years. Carcinomas are more frequent than sarcomas. Metastases are rare. Tumours of the sphenoid and frontal sinuses are extremely rare.