

NAME: EKPO VALENTINO

MATRIC NUMBER: 18/MHS01/142

COURSE: EMBRYOLOGY

DEPARTMENT: MEDICINE AND SURGERY (200L)

DATE: 15TH APRIL 2020

ASSIGNMENT

QUESTION 1: DISCUSS OVULATION

DEFINITION

Ovulation is defined as the release of a mature secondary oocyte from the ovarian cycle.

Ovulation is the release of eggs from the ovaries. In women, this event occurs when the ovarian follicles rupture and release the secondary oocyte ovarian cells. After ovulation, during the luteal phase, the egg will be available to be fertilized by sperm.

The ovarian follicle undergoes a sudden growth sprut under the influence the Follicle Stimulating Hormone and the Luteinizing hormone, around mid-cycle (14 days in an “average” 28-day menstrual cycle). This growth sprut produces a cystic swelling or bulge on the surface of the ovary. A small avascular spot, called STIGMA, soon appears in the swelling.

The secondary follicle grows rapidly to about 25mm to become the mature vesicular follicle few days before ovulation, under the influence of female stimulating hormones and luteinizing hormone. There is an abrupt increase in luteinizing hormone in coincidence with final development of vesicular follicle that causes: The primary oocyte to complete meiosis 1 and also causes the follicle to enter the pre ovulatory mature vesicular stage

Meiosis 2 is also initiated but the secondary oocyte is arrested in metaphase 2 approximately 2 to 3 hours before ovulation by cytostatic factors

for the oocyte to be released, 2 events occur which are caused by LH surge:

- it increases **collagenase activity**, resulting in **digestion of collagen fibers** (connective tissue) surrounding the follicle
- Prostaglandin levels also increase in response to the LH surge and cause local muscular contractions in the ovarian wall
 - Those contractions extrude the oocyte, which together with its surrounding follicular (granulosa) cells from the region of the cumulus oophorus,
 - this causes **ovulation in which oocyte floats out of the ovary**
 - Some of the cumulus oophorus cells then rearrange themselves around the zona pellucida to form the **corona radiata**

NOTE: Ovulation is triggered by a surge of LH production. Ovulation usually follows the LH peak by 12 to 24 hours. The **LH surge**, elicited by the high estrogen level in the blood, appears to cause the stigma to balloon out, forming a vesicle

CLINICAL CORELATES

During ovulation, some women feel a variable amount of abdominal pain called **mittelschmerz** also known as **middle pain** because it normally occurs near the middle of the menstrual cycle

-In these cases, ovulation results in slight bleeding into the peritoneal cavity, which results in sudden constant pain in the lower abdomen.

-Mittelschmerz may be used as a symptom of ovulation

Other signs of ovulation include

1. Changes in the cervical mucus:

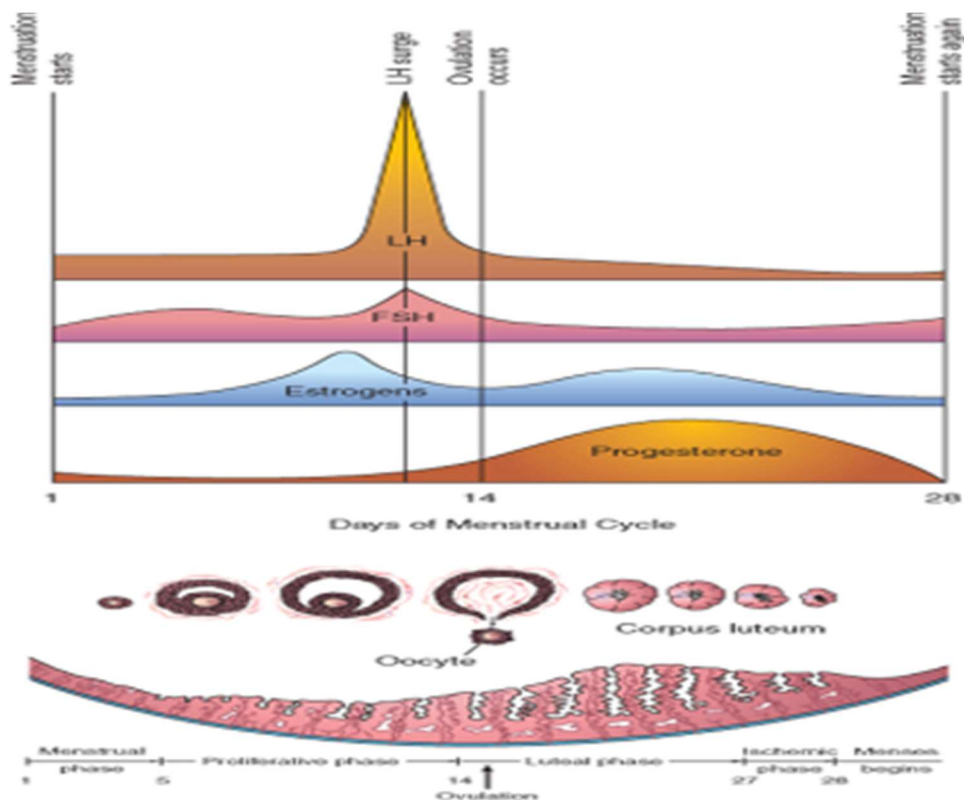
-When you're not ovulating, cervical mucus may appear sticky, creamy, or may be entirely absent

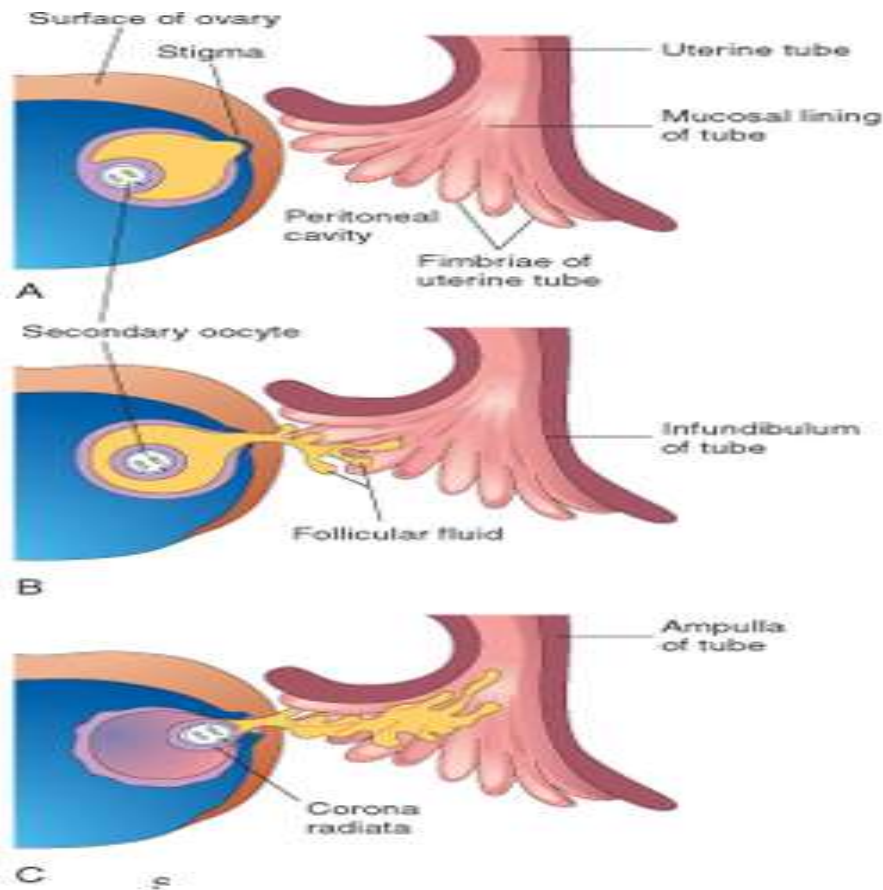
-As ovulation approaches, cervical mucus becomes more abundant, takes on a watery to raw-egg-white-like consistency (slippery egg white looking discharge), and stretches up to an inch or more between your fingers

2. Increase libido/ increase urge for sex

3. Tenderness of the breast

4. Swollen vagina or vulva





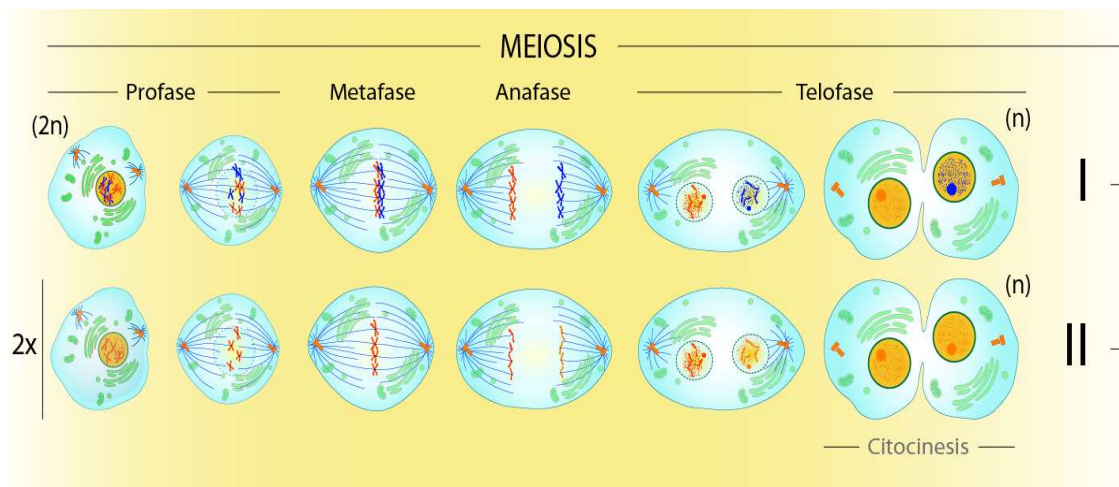
QUESTION 2: DIFFERENCES BETWEEN MEIOSIS 1 AND MEIOSIS 2

DEFINITION:

Meiosis is a type of cell division that results in four daughter cells each with half the number of chromosomes of the parent cell, as in the production of gametes and plant spores

MEIOSIS 1	MEIOSIS 2
Reduces the chromosome number in the daughter cell	Equalizes the chromosome number of both parent and daughter cells
It is a heterotypic division	It is a homotypic division
Homologous chromosomes present at the beginning	Individual, bivalent chromosomes are present at the beginning
Preceded by interphase	No interphase takes place
Chromosomal crossovers occurs in prophase 1	No chromosomal crossovers during prophase 2
A complex division and takes more time	Comparatively less simple and takes less time
Individual chromosomes are present in daughter nuclei	Sister chromosomes are present in daughter nuclei

DIAGRAMMATIC DIFFERENCE BETWEEN MEIOSIS 1 AND MEIOSIS 2



QUESTION 3: DISCUSS THE DIFFERENT STAGES INVOLVED IN FERTILIZATION

DEFINITION: Human fertilization is a sequence of coordinated events that involves the union of a human egg and sperm, usually occurring in the ampulla of the fallopian tube. The result of this union is the production of a zygote cell, or fertilized egg, initiating prenatal development

STAGES INVOLVED IN FERTILIZATION

1. Passing of sperm the corona radiata
2. Penetration of the zona pellucida
3. Fusion of plasma membrane of sperm and oocyte
4. Completion of second meiotic division and formation of female pro nuclei
5. Formation of male pro nucleus
6. Formation of zygote

1. **PASSAGE OF A SPERM THROUGH THE CORONA RADIATA:**

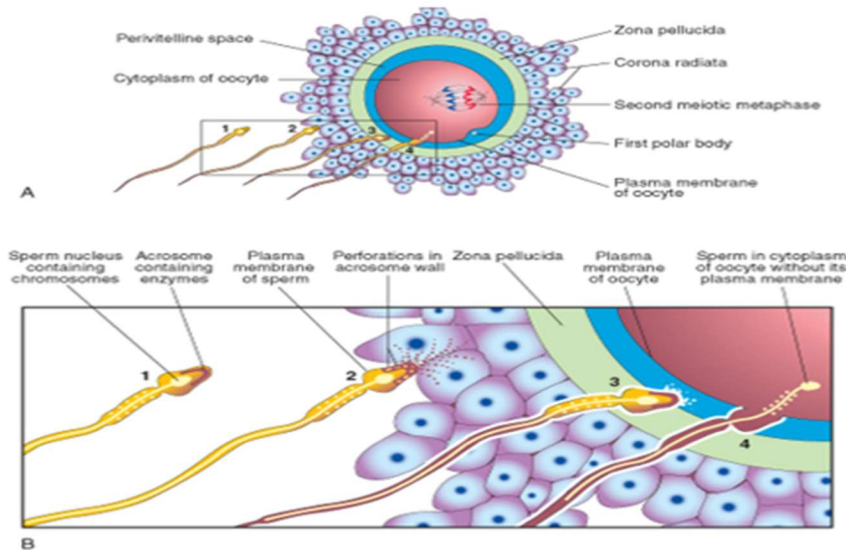
During capacitation the glycoprotein material and seminal plasma protein on the region of the head/ cell membrane is removed .For sperms to pass through the corona radiata, they must have been capacitated (removal of the glycoprotein coat and seminal plasma proteins from the plasma membrane that overlies the acrosomal region of the spermatozoa). Only capacitated sperms can pass freely through the corona radiata

2. **PENETRATION OF THE ZONA PELLUCIDA:**

For sperm to pass the zona pellucida, the acrosome binds to the zona pellucida. The zona is a glycoprotein shell surrounding the egg that facilitates and maintains sperm binding and induces the acrosome reaction. The intact acrosome of the sperm **binds** with a zona glycoprotein (ZP3/ zona protein 3) on the zona pellucida. Release of acrosomal enzymes (acrosin) allows sperm to penetrate the zona pellucida, thereby coming in contact with the plasma membrane of the oocyte

As soon as the head of a sperm comes in contact with the oocyte surface, the permeability of the zona pellucida changes. When a sperm comes in contact with the oocyte surface, lysosomal enzymes are released from cortical granules lining the plasma membrane of the oocyte. In turn, these enzymes alter properties of the zona pellucida to:

- prevent sperm penetration and
- inactivate binding sites for spermatozoa on the zona pellucida surface
- only one sperm seems to be able to penetrate the oocyte



3. **FUSION OF PLASMA MEMBRANES OF THE OOCYTE AND SPERM**

The plasma or cell membranes of the oocyte and sperm fuse and break down at the area of fusion. The head and tail of the sperm enter the cytoplasm of the oocyte, but the sperm's plasma membrane remains behind

4. **COMPLETION OF THE SECOND MEIOTIC DIVISION OF OOCYTE AND FORMATION OF FEMALE PRONUCLEUS**

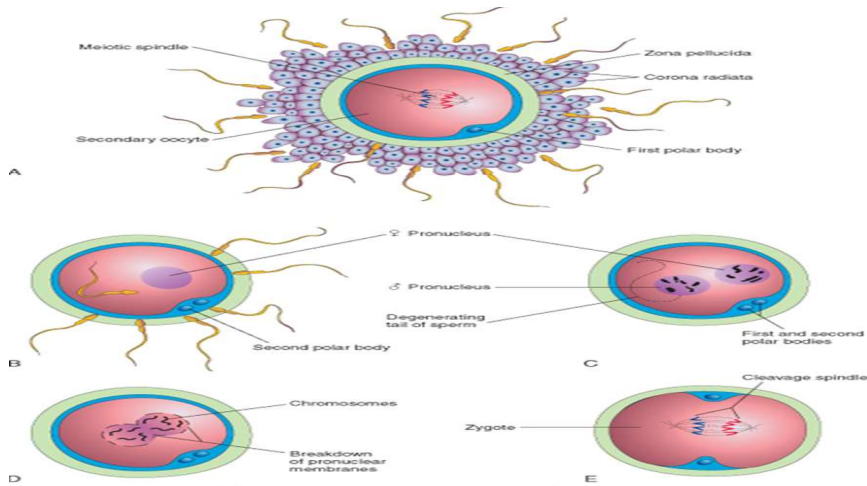
Penetration of the oocyte by a sperm activates the oocyte into completing the second meiotic division and forming a mature oocyte and a second polar body. The nucleus of the mature ovum/oocyte is now called the female pronucleus

5. **FORMATION OF THE MALE PRONUCLEUS**

Within the cytoplasm of the oocyte, the nucleus of the sperm enlarges to form the male pronucleus and the tail of the sperm degenerates. Since all sperm mitochondria degenerate, all mitochondria within the zygote are of maternal origin (i.e., all mitochondrial DNA is of maternal origin). Morphologically, the male and female pronuclei are indistinguishable. The oocyte now contains 2 pronuclei, each having haploid number of chromosomes (23). The oocyte containing two haploid pronuclei is called an **ootid**.

6. **FORMATION OF A ZYGOTE**

The 2 pronuclei fuse into a single diploid aggregation of chromosomes, the ootid becomes a zygote. The chromosomes in the zygote become arranged on a cleavage spindle in preparation for cleavage of the zygote



CLINICAL CORRELATES

- The syncytiotrophoblast produces a hormone called the human chorionic gonadotropin (hCG), which enters the maternal blood via lacunae keeps the corpus luteum secreting estrogens and progesterone
- hCG maintains the hormonal activity of the corpus luteum in the ovary during pregnancy.
- HCG can be detected in maternal blood or urine as early as day 10 of pregnancy and is the basis for pregnancy tests
- Enough hCG is produced by the syncytiotrophoblast at the end of the second week to give a positive pregnancy test, even though the woman is probably unaware that she is pregnant.
- Blastocysts may implant outside the uterus.
- These implantation results in what is known as *ectopic pregnancies*.
- About 95-97% of ectopic pregnancies are in the ampulla and isthmus of the uterine tube.
- The highest rate are in women who are 35 & above and non-white women, however, all women of child bearing age are at risk of ectopic pregnancies.

QUESTION 4: DIFFERENTIATE BETWEEN MONOZYGOTIC TWINS AND DIZYGOTIC TWINS

The nurturing of two conspectuses at the same time is termed twinning. Two infants born at the same time are called twins. Similarly, there can be birth of 3 (triplets), 4 (quadruplets), or more at the same time

- There are 2 types of twins:

(a) Monozygotic /identical twins

(b) dizygotic/fraternal twins

MONOZYGOTIC (IDENTICAL) TWINS

The monozygotic twins result from fertilization of **one secondary oocyte** by **one sperm**. The resultant zygote forms a blastocyst in which inner cell mass (**embryoblast**) **splits into 2**

DIZYGOTIC (FRATERNAL) TWINS

offspring that develop from two zygotes but share a common uterine environment, and would be born at the same birth.

MONOZYGOTIC TWINS	DIZYGOTIC TWINS
About 1/3 twins are monozygotic	About 2/3 twins are monozygotic
It involves 1 sperm and 1 ovum	It involves 2 sperms and 2 ova
They are identical	Presence of dischorionic and Diaminiotic twins
Their type of placenta depends on the time of splitting embryo	Presence of chorionic tissues between 2 amniotic sacs
Incidence is dependent of race , age, parity	Incidence is dependent of race , age , parity and ovulation inducing drugs

CLINICAL CORRELATES

Conjoint (Siamese) twins:

- This condition is seen in **monozygotic twins**
- it occurs when the **inner cell mass (embryoblast)** does **not completely split**
- In this condition, the 2 fetuses are joined to each other by a **tissue bridge**

Classification of conjoint twins

- The conjoint twins are classified into following **four types based** on the site and extent of fusion

- (a) Craniophagus: Fusion of heads
- (b) Thoracophagus: Fusion of thorax
- (c) Cephalothoracophagus: Fusion of head and thorax
- (d) Pygophagus: Fusion of sacral regions

- *The conjoint twins can be separated only if they have no vital parts in common.*

