

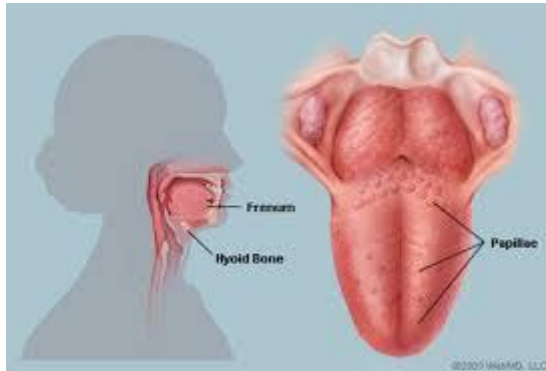
**NAME: SALISU FAROUK**

**MATRIC NO.: 17/MHS01/293**

**COURSE: GROSS ANATOMY OF THE HEAD AND NECK**

**1) Discuss the anatomy of the tongue and comment on its applied anatomy.**

**THE TONGUE**



The tongue is a mobile muscular organ covered with mucous membrane which can assume a variety of shapes and positions.

The tongue is located partly in the oral cavity and partly in the oropharynx. It is inferior to the palates (soft palate and hard palate), posterior to the teeth.

The tongue has the following functions:

- i. Articulation – forming words during speaking
- ii. Deglutition (swallowing) – squeezing food into the oropharynx
- iii. Mastication (chewing)
- iv. Taste
- v. Oral cleansing

**Parts and surfaces of the tongue**

The tongue has three parts namely; the root, body and apex.

- i. The root of the tongue: this part is the attached posterior portion, extending between the mandible, hyoid and the nearly vertical posterior surface of the tongue.
- ii. The body of the tongue: this part is anterior, approximately two-thirds of the tongue between the root and apex.
- iii. The apex of the tongue: this is the tip of the tongue. It is the anterior end of the body, which rests against the incisor teeth.

The body and the apex of the tongue are extremely mobile.

## Surfaces of the tongue

The tongue has two surfaces:

- i. The top surface: the more extensive superior and posterior surface is known as the *dorsum of the tongue*.
- ii. The underside surface: this is the inferior surface of the tongue and usually rests against the floor of the mouth.

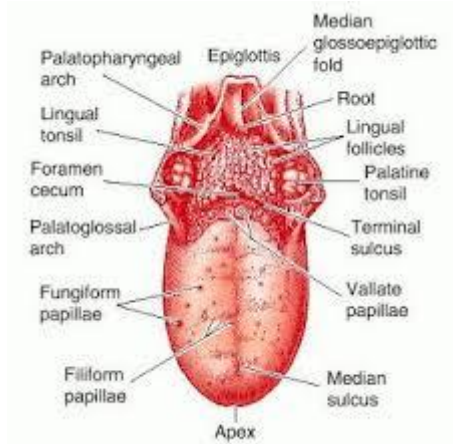
The margin of the tongue separating the two surfaces is related on each side to the lingual gingivae and lateral teeth.

### The dorsum of the tongue:

This is characterized by a V-shaped groove, ***the terminal sulcus of the tongue***. The angle of the groove points posteriorly to the foramen cecum. The terminal sulcus divides the dorsum of the tongue transversely into a ***presulcal anterior part*** in the oral cavity and a ***postsulcal posterior part*** in the oropharynx.

- i. The presulcal anterior part: this part is divided by a midline groove into left and right parts. The mucosa of the anterior part of the tongue is relatively thin and closely attached to the underlying muscle. It has a rough texture due to the presence of numerous small lingual papillae:
  - Vallate papillae: these are large and flat topped. They lie directly anterior to the terminal sulcus and are arranged in a v-shaped row. The papillae are surrounded by deep circular trenches the walls of which are studded with taste buds. The ducts of the serous glands open into these trenches.
  - Foliate papillae: these are small lateral folds of the lingual mucosa. There are four or five vertical folds and their size and shape vary. They are poorly developed in humans. They are located on the sides at the back of the tongue on each side, anterior to the palatoglossal arch of the fauces.
  - Filiform papillae: long and numerous, contain afferent nerve endings that are sensitive to touch. These scaly, conical projections are pinkish gray and are arranged in v-shaped rows that are parallel to the terminal sulcus, except at the apex where they tend to be arranged transversely.
  - Fungiform papillae: mushroom shaped pink or red spots scattered among the filiform papillae, but most numerous at the apex and margins of the tongue.

The *vallate*, *foliate* and most of the ***fungiform papillae*** contain taste receptors in the taste buds.



- ii. The postsulcal posterior part: the mucosa of the posterior tongue is thick and freely movable. It has no lingual papillae, but the underlying lymph nodules give this part of the tongue an irregular, cobblestone appearance. The lymphoid nodules are collectively known as the **lymphoid tonsil**.

**The inferior surface of the tongue:** This surface of the tongue is covered by a thin, transparent, mucous membrane. It is connected to the floor of the mouth by a midline fold called the **frenulum of the tongue**. The frenulum allows the apex of the tongue to move freely. On each side of the frenulum lies a deep lingual vein. A sublingual caruncle (papilla) is present on each side of the base of the frenulum of the tongue that includes the opening of the submandibular duct.

## **MUSCLES OF THE TONGUE**

The tongue is essentially a mass of muscle that is mostly covered by mucosa. The muscles of the tongue are divided into two:

1. Extrinsic muscle: the extrinsic muscles alter the position of the tongue
2. Intrinsic muscle: the intrinsic muscles alter the shape of the tongue.

There are four extrinsic muscles and four intrinsic muscles in each half of the tongue. These are separated by a median fibrous lingual septum which merges posteriorly with the lingual aponeurosis (a tough sheet of connective tissue where the muscles insert)

**The extrinsic muscles:** these muscles originate outside the tongue but they attach to it. They mainly move the tongue but they can alter its shape as well. There are four extrinsic muscles which are:

- Genioglossus
- Hyoglossus
- Styloglossus

- Palatoglossus

**The intrinsic muscles:** the intrinsic muscles have their attachments entirely within the tongue and have no attachments to bone. The intrinsic muscles are grouped into two:

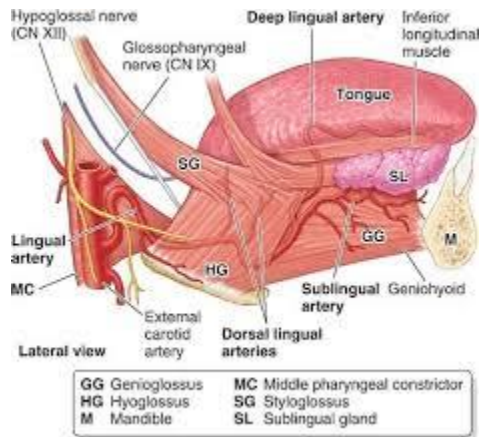
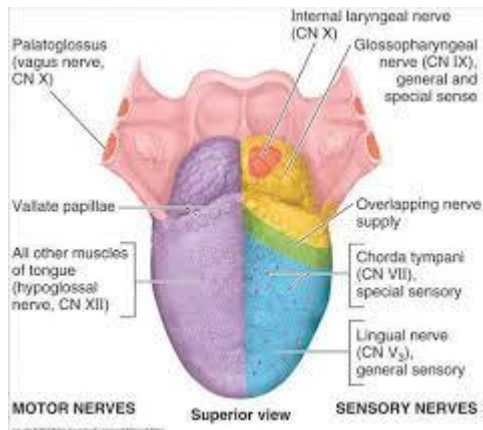
- The superior and inferior longitudinal muscles: acts together to make the tongue short and thick and to retract a protruded tongue.
- The transverse and vertical muscles: act simultaneously to make the tongue long and narrow, which may push the tongue against the incisor teeth or protrude the tongue from the open mouth (especially when acting with the posterior inferior part of the Genioglossus).

### **INNERVATION OF THE TONGUE**

- Motor innervations: All muscles of the tongue except the palatoglossus receive motor innervations from the hypoglossal nerve (CNXVII). Palatoglossus is a palatine muscle supplied by the pharyngeal plexus.
- Sensory innervations:
  - a) Anterior two-thirds:
    - i. For general sensation (touch and temperature): the mucosa of the anterior two-thirds of the tongue is supplied by the lingual nerve (a branch of CNV<sub>3</sub> (maxillary nerve)).
    - ii. For special sensation (taste): the anterior two-thirds of the tongue except for the vallate papillae is supplied by the chorda tympani nerve, a branch of CN VII (facial nerve).  
The chorda tympani joins the lingual nerve in the infratemporal fossa and runs anteriorly in its sheath.
  - b) Posterior third & Vallate papillae: For general and special sensation, the mucosa of the posterior third and the vallate papillae are supplied by the lingual branch of the glossopharyngeal nerve (CN IX).

Twigs of the internal laryngeal nerve (a branch of the vagus nerve) supplies mostly general but some special sensation to a small area of the tongue just anterior to the epiglottis. These mostly sensory nerves also carry parasympathetic secretomotor fibers to serous glands in the tongue.

There are four basic taste sensations; sweet, salty, sour and bitter. These tastes are ascribed to certain areas of the tongue which are more sensitive to these tastes. Other tastes expressed by gourmets are influenced by olfactory sensation (smell & aroma).

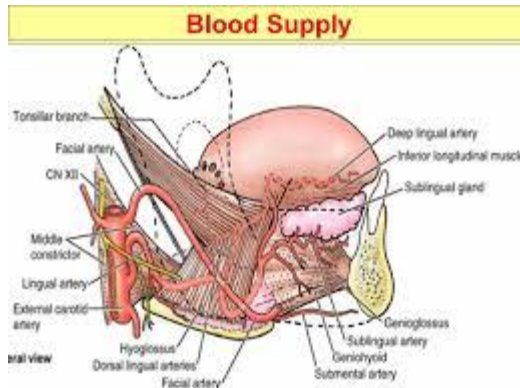


## VASCULATURE OF THE TONGUE

- 1) **ARTERIAL SUPPLY:** the arteries of the tongue are derived from the lingual artery.
  - The dorsal lingual arteries: supplies the root of the tongue
  - The deep lingual arteries: supplies the body of the tongue

The deep lingual arteries communicate with each other near the apex of the tongue.

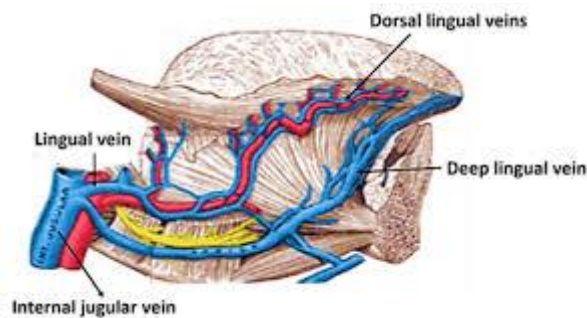
The dorsal lingual arteries are prevented from communicating by the lingual septum.



2) **VENOUS DRAINAGE:** the veins of the tongue are:

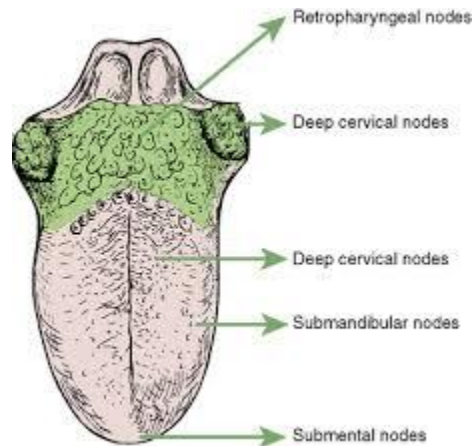
- The dorsal lingual veins: accompanies the lingual artery
- The deep lingual veins: begins at the apex of the tongue, runs posteriorly beside the lingua frenulum to join the sublingual vein. The sublingual veins in elderly people are often varicose.

Some or all the veins may drain into the internal jugular vein directly or indirectly by joining first to form the lingual vein that accompanies the initial part of the lingual artery.



3) **LYMPHATIC DRAINAGE OF THE TONGUE:** most of the lymphatic drainage converges toward and follows the tip of the tongue except lymph from the tip of the tongue, frenulum and central lower lip that runs an independent course. The lymph from different areas of the tongue follows four routes:

- i. Lymph from the root of the tongue drains bilaterally into the superior deep cervical lymph nodes
  - ii. Lymph from the medial part of the body drains bilaterally into the inferior deep cervical lymph nodes
  - iii. Lymph from the right and left lateral parts of the body drains into the submandibular lymph nodes on the ipsilateral side
  - iv. The apex and frenulum drain into the submental lymph nodes
- All lymph from the tongue ultimately drains to the deep cervical node which passes via the jugular venous trunks into the venous system.



### **CLINICAL ANATOMY**

1. **Lingual frenectomy:** a frenulum of the tongue (frenum) extending farther anteriorly towards the apex (tongue-tie) interferes with tongue movement and may affect speech. In unusual cases, frenectomy (cutting the frenulum) in children may be needed to improve speech.
2. **Lingual carcinoma:** a lingual carcinoma in the posterior part of the tongue metastasizes to the superior deep cervical lymph nodes on both sides. However, a tumor in the anterior part usually does not metastasize to the inferior deep cervical lymph nodes until late in the disease. Because the nodes are closely related to the internal jugular vein, metastases from the tongue may be distributed through the submental and submandibular regions and along the internal jugular veins in the neck.
3. **Injury to the hypoglossal nerve:** trauma, such as fractured mandible, may injure the hypoglossal nerve (CN XII), resulting in paralysis and eventual atrophy of one side of the tongue. The tongue deviates to the paralyzed side during protrusion because of the action of the unaffected Genioglossus muscle on the other side.
4. **Paralysis of Genioglossus:** when the Genioglossus muscle is paralyzed, the tongue has a tendency to fall posteriorly, obstructing the airway and presenting the risk of suffocation.

### **2) Write an essay on air sinuses**

Air sinuses are also known as paranasal sinuses. They are paired air-filled extensions of the respiratory part of the nasal cavity into the following cranial bones: *frontal, ethmoid, sphenoid and maxilla*. The sinuses are named according to the bones they occupy.

- a) **Frontal sinuses:** The left and right frontal sinuses are between the outer and inner tables of the frontal bone, posterior to the superciliary arches and the root of the nose. The right and left frontal sinuses each drain through a frontonasal duct into the ethmoidal infundibulum, which opens into the semilunar hiatus of the middle nasal meatus. The frontal sinuses are innervated by branches of the supra-orbital nerves (CN V<sub>1</sub>). The frontal sinus varies in size from approximately 5mm to large spaces extending laterally into the greater wings of the sphenoid. The frontal sinus has two parts:
- **Vertical part:** located in the squamous part of the frontal bone
  - **Horizontal part:** located in the orbital part of the frontal bone.
- One or both parts may be large or small. When the supra-orbital part is large, it forms the floor of the anterior cranial fossa and its floor forms the roof of the orbit.
- b) **Ethmoidal cells:** the ethmoidal cells (sinuses) are small invaginations of the mucous membrane of the middle and superior nasal meatus into the ethmoid bone between the nasal cavity and the orbit. There are three types of ethmoidal cells;
- Anterior ethmoidal cells: these cells drain directly or indirectly into the middle nasal meatus through the ethmoidal infundibulum.
  - Middle ethmoidal cells: the middle ethmoidal cells open directly into the middle meatus and are sometimes called the 'bullar cells' because they form the ethmoidal bulla (a swelling on the superior border of the semilunar hiatus).
  - The posterior ethmoidal cells: opens directly into the superior meatus.

The ethmoidal cells are supplied by the anterior and posterior ethmoidal branches of the nasociliary nerves (CN V<sub>1</sub>).

- c) **Sphenoidal sinuses:** the sphenoidal sinuses are located in the body of the sphenoid, but they may extend into the wings of this bone. They are unevenly divided and separated by a bony septum. Due to the extensive pneumatization (formation of air cells), the body of the sphenoid is fragile. Only thin plates of bones separate the sinuses from important structures which are (internal carotid arteries, optic nerves and optic chiasm, pituitary gland and the cavernous sinuses). The sphenoidal sinuses are derived from a posterior ethmoidal cell which begins to invade the sphenoid at approximately 2 years of age. In some people, several posterior ethmoidal cells invade the sphenoid, giving rise to



multiple sphenoidal sinuses that open separately into the sphenoid-ethmoidal recess.

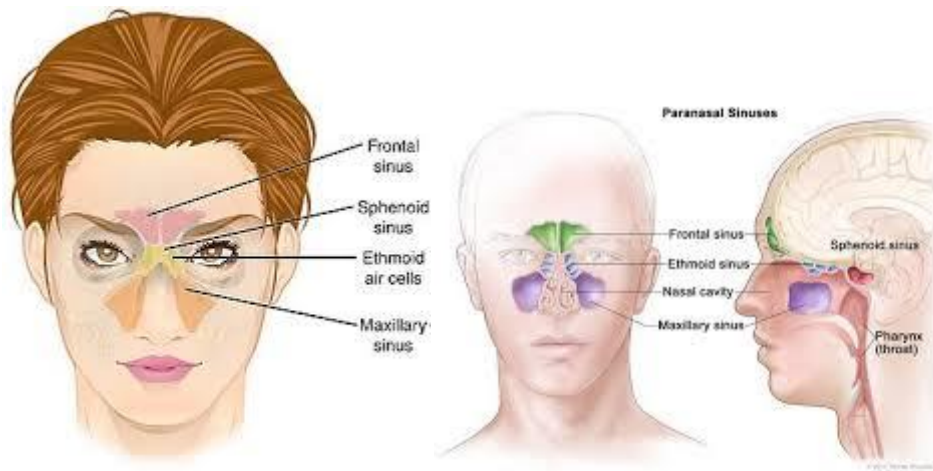
The posterior ethmoidal arteries and the posterior ethmoidal nerves supply the sphenoidal sinuses.

d) **Maxillary sinuses:** these are the largest of the paranasal sinuses. They occupy the bodies of the maxillae and communicate with the middle nasal meatus. The maxillary sinus has parts:

- **The apex:** extends towards and often into the zygomatic bone
- **The base:** forms the inferior part of the lateral wall of the nasal cavity
- **The roof:** formed by the floor of the orbit
- **The floor:** formed by the alveolar part of the maxilla.

Each maxillary drains by one or more openings, the maxillary ostium into the middle meatus of the nasal cavity by way of the semilunar hiatus.

The arterial supply of the maxillary sinus is mainly from the superior alveolar branches of the maxillary artery. Branches of the descending and greater palatine arteries supply the floor of the sinus. Branches of the maxillary nerve supply the maxillary sinuses which are the: anterior, middle and posterior superior alveolar nerves.



## **CLINICAL ANATOMY**

1. **Sinusitis:** because the paranasal sinuses are continuous with the nasal cavities through the apertures that open into them, infection may spread from the nasal cavities, producing inflammation and swelling of the mucosa of the sinuses (sinusitis) and local pain. Sometimes, several sinuses are inflamed (pansinusitis), and the swelling of the mucosa may block one or more openings of the sinuses into the nasal cavities.

- 2. Infection of ethmoidal cells:** if nasal drainage is blocked, infection of the ethmoidal cells may break through the fragile medial wall of the orbit. Severe infections from this source may cause blindness because some posterior ethmoidal cells lie close to the optic canal, which give passage to the optic nerve and ophthalmic artery. Spread of infection from these cells could also affect the dural sheath of the optic nerve causing optic neuritis.
- 3. Infection of the maxillary sinuses:** the maxillary sinuses are the most commonly affected, probably because their Ostia (openings) are commonly small and located high on their superomedial walls. When the mucous membrane of the sinus is congested, the maxillary Ostia are often affected. Because of the high location of the Ostia, the sinus is not drained when the head is erect, however, due to the location of the sinuses on the left and right, the sinuses are easily drained when lying on one's side.
- 4. Relationship of teeth to maxillary sinus:** the close proximity of the three maxillary molar teeth to the floor of the maxillary sinus poses potentially serious problems. During removal of a maxillary tooth, a fracture of a root of a tooth may occur. If proper retrieval methods are not used, a piece of the tooth may be driven into the maxillary sinus, thus creating a communication between the maxillary sinus and the oral cavity.