

**NAME: USIGBE JEMIMAH OTALOWEBE**

**MATRIC NO.: 18/MHS01/366**

**DEPARTMENT: MEDICINE AND SURGERY**

**COUSRE: EMBRYOLOGY**

**ASSIGNMENT**

**1) DISCUSS THE SECOND WEEK OF DEVELOPMENT.**

**ANSWER:**

### **SECOND WEEK OF DEVELOPMENT**

There are series of events that takes place during the second week of development and they include;

- 1) Completion of implantation of the blastocyst;
- 2) Formation of bilaminar embryonic disc (epiblast and hypoblast) ;
- 3) Formation of extraembryonic structures (amniotic cavity, amnion, umbilical vesicle [yolk sac], connecting stalk and chorionic sac).

### **DAY 8:**

On the eighth day of development, the blastocyst is partially embedded in the endometrium slowly. In the area over the embryoblast, the trophoblast has differentiated into two layers:

- An inner layer of mononucleated cells, the cytotrophoblast;
- An outer multinucleated zone without distinct cell boundaries, the syncytiotrophoblast.

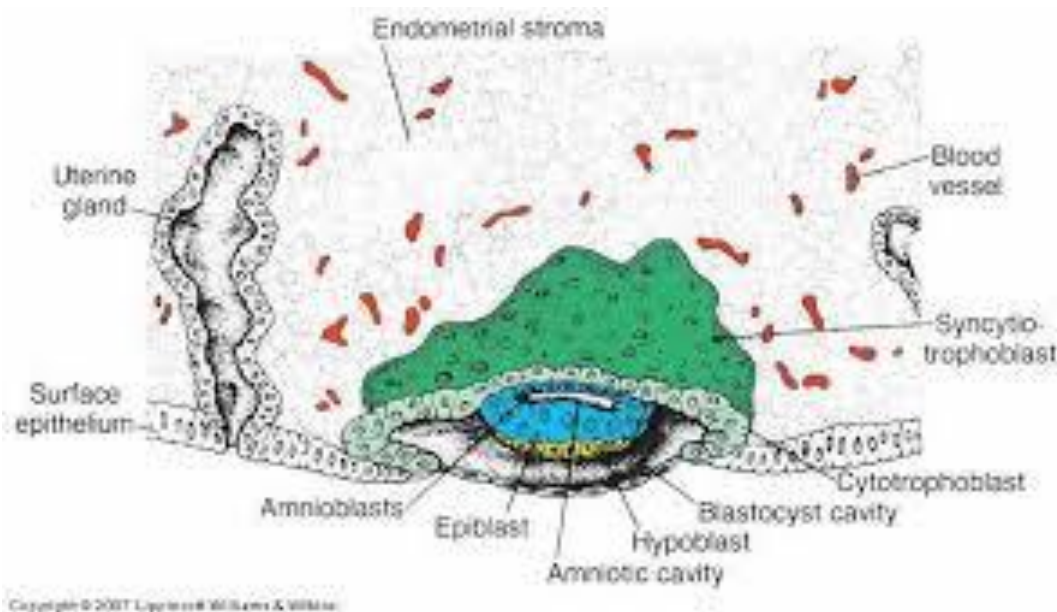
Mitotic figures are found in the cytotrophoblast but not in the syncytiotrophoblast. Thus, cells in the cytotrophoblast divide and

migrate into the syncytiotrophoblast, where they fuse and lose their individual cell membranes.

Cells of the inner cell mass or embryoblast also differentiate into two layers:

- A layer of small cuboidal cells adjacent to the blastocyst cavity, known as the hypoblast layer;
- A layer of high columnar cells adjacent to the amniotic cavity, the epiblast layer.

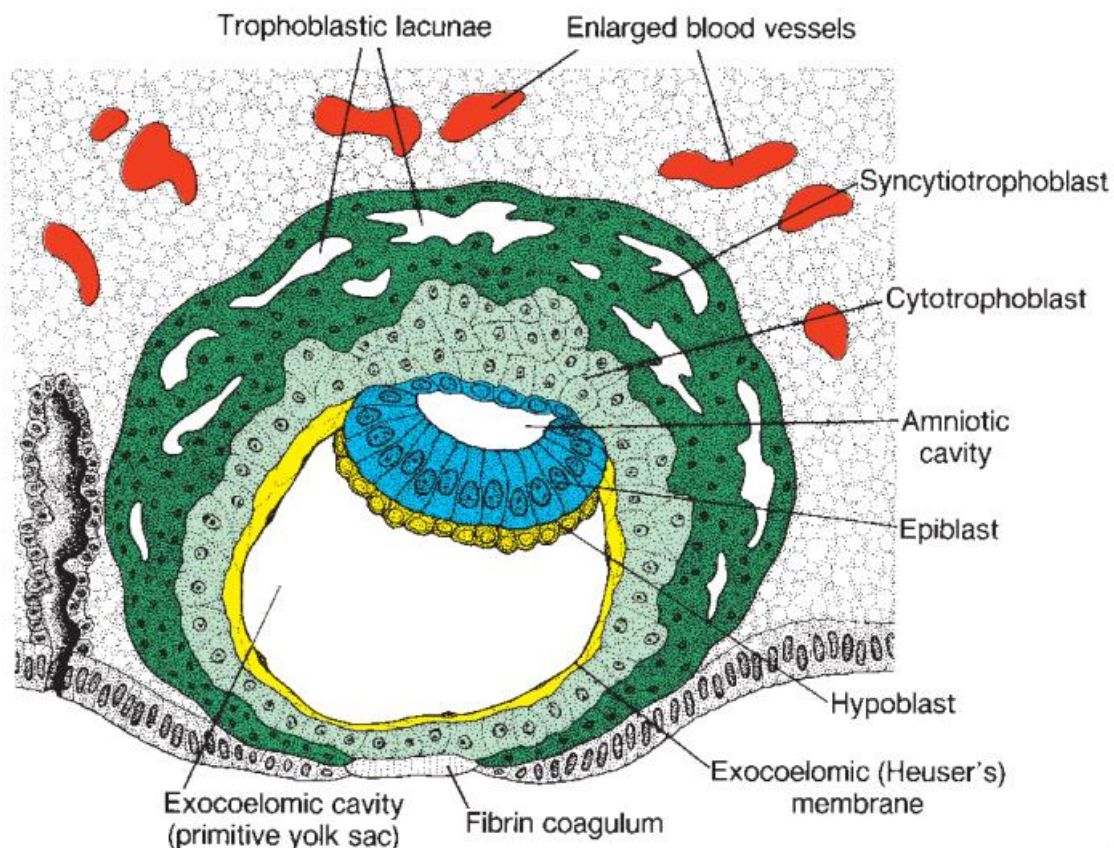
Together, the layers form a flat disc. At the same time, a small cavity appears within the epiblast. This cavity enlarges to become the amniotic cavity. Epiblast cells adjacent to the cytotrophoblast are called amnioblasts, together with the rest of the epiblast, they line the amniotic cavity. The endometrium adjacent to the implantation site is edematous and highly vascular. The large, tortuous glands secrete abundant glycogen and mucus.



## DAY 9:

The blastocyst is more deeply embedded in the endometrium, and the penetration defect in the surface epithelium is closed by a fibrin coagulum. The trophoblast shows considerable progress in development, particularly at the embryonic pole, where vacuoles fuse, they form large lacunae, and this phase of trophoblast development is thus known as the lacunar stage.

At the abembryonic pole, meanwhile, flattened cells probably originating from the hypoblast form a thin membrane, the exocoelomic (Heuser) membrane that lines the inner surface of the cytotrophoblast. This membrane, together with the hypoblast, forms the lining of the exocoelomic cavity, or primitive yolk sac.



## **DAYS 11 AND 12:**

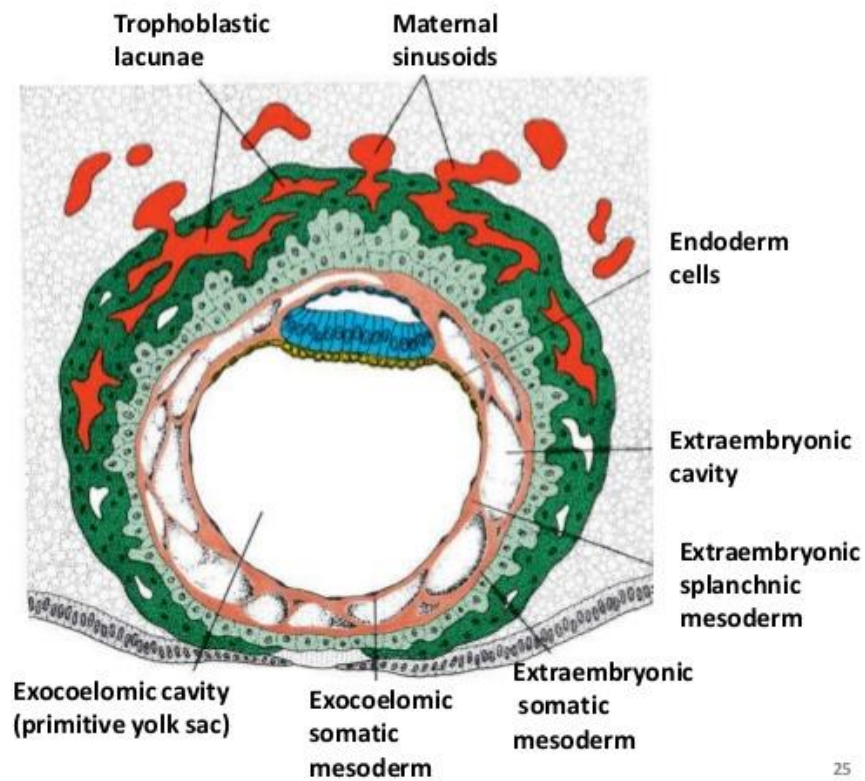
By the 11<sup>th</sup> to the 12<sup>th</sup> day of development, the blastocyst is completely embedded in the endometrial stroma, and the surface of the epithelium almost entirely covers the original defect in the uterine wall. The blastocyst now produces a slight protrusion into the lumen of the uterus. The trophoblast is characterized by lacunar spaces in the syncytium that form an intercommunicating network. This network is particularly evident at the embryonic pole, the trophoblast still consists mainly of cytotrophoblastic cells.

Concurrently, cells of the syncytiotrophoblast penetrate deeper into the stroma and erode the endothelial lining of the maternal capillaries. These capillaries, which are congested and dilated, are known as sinusoids. The syncytial lacunae become continuous with the sinusoids, and maternal blood enters the lacunar system. As the trophoblast continues to erode more and more sinusoids, maternal blood begins to flow through the trophoblastic system, establishing the uteroplacental circulation.

In the meantime, a new population of cells appears between the inner surface of the cytotrophoblast and the outer surface of the exocoelomic cavity. These cells, derived from the yolk sac cells, form a fine, loose connective tissue, the extraembryonic mesoderm, which eventually fills all of the space between the trophoblast externally and the amnion and exocoelomic membrane internally. Soon, large cavities develop in extraembryonic mesoderm, and when these become confluent, they form a new space known as extraembryonic cavity, or chorionic cavity. This space surrounds the primitive yolk sac and amniotic cavity, except where the germ disc is connected to the

trophoblast by the connecting stalk. The extraembryonic mesoderm lining the cytotrophoblast and amnion is called the extraembryonic somatic mesoderm; the lining covering the yolk sac is called the extraembryonic splanchnic mesoderm.

Growth of the bilaminar disc is relatively slow compared with that of the trophoblast; consequently, the disc remains very small. Cells of the endometrium, meanwhile, become polyhedral and loaded with glycogen and lipids; intercellular spaces are filled with extravasate, and the tissue is edematous. These changes, known as the decidua reaction, at first, are confined to the area immediately surrounding the implantation site but soon occur throughout the endometrium.



## DAY 13

By the 13<sup>th</sup> day of development, the surface defect in the endometrium has usually healed. Occasionally, however, bleeding occurs at the implantation site as a result of increased blood flow into the lacunar spaces. Because this bleeding occurs near the 28<sup>th</sup> day of the menstrual cycle, it may be confused with normal menstruation and, therefore, may cause inaccuracy in determining the expected delivery date.

The trophoblast is characterized by villous structures. Cells of the cytotrophoblast proliferate locally and penetrate into the syncytiotrophoblast, forming cellular columns surrounded by syncytium. Cellular columns with the syncytial covering are known as primary villi.

In the meantime, the hypoblast produces additional cells that migrate along the inside of the exocoelomic membrane. These cells proliferate and gradually form a new cavity within the exocoelomic cavity. This new cavity is known as the secondary yolk sac or definitive yolk sac. This yolk sac is much smaller than the original exocoelomic cavity or primitive yolk sac. During its formation, large portions of the exocoelomic cavity are pinched off. These portions are represented by exocoelomic cysts, which are often found in the extraembryonic coelom or chorionic cavity.

Meanwhile, the extraembryonic coelom expands and forms a large cavity, the chorionic cavity. The extraembryonic mesoderm lining



the inside of the cytotrophoblast is then known as the chorionic plate. The only place where the extraembryonic mesoderm traverses the chorionic cavity is in the connecting stalk. With development of blood vessels, the stalk becomes the umbilical cord.

- **Chorionic cavity:** The extraembryonic coelom expands and form a large cavity, the chorionic cavity.

- **Chorionic plate:** Extraembryonic mesoderm lining the inside of the cytotrophoblast is known as chorionic plate.

