

**NAME: UMEOKEKE MARY KENECHUKWU**

**MATRIC NUMBER: 18/MHS01/362**

**LEVEL: 200L**

**DEPARTMENT: MEDICINE AND SURGERY**

**COURSE: ANATOMY (EMBRIOLOGY)**

**DATE: 12<sup>TH</sup> MAY 2020**

**ASSIGNMENT1: WRITE ON THE SECOND WEEK OF DEVELOPMENT**

### **INTRODUCTION: HUMAN EMBYONIC DEVELOPMENT**

Human embryonic development, or human embryogenesis, refers to the development and formation of the human embryo. It is characterized by the processes of cell division and cellular differentiation of the embryo that occurs during the early stages of development. In biological terms, the development of the human body entails growth from a one-celled zygote to an adult human being. Fertilization occurs when the sperm cell successfully enters and fuses with an egg cell (ovum). Human embryology is the study of this development during the first eight weeks after fertilization. The normal period of gestation (pregnancy) is about nine months or 40 weeks.

### **INTRODUCTION: SECOND WEEK OF EMBRYONIC DEVELOPMENT**

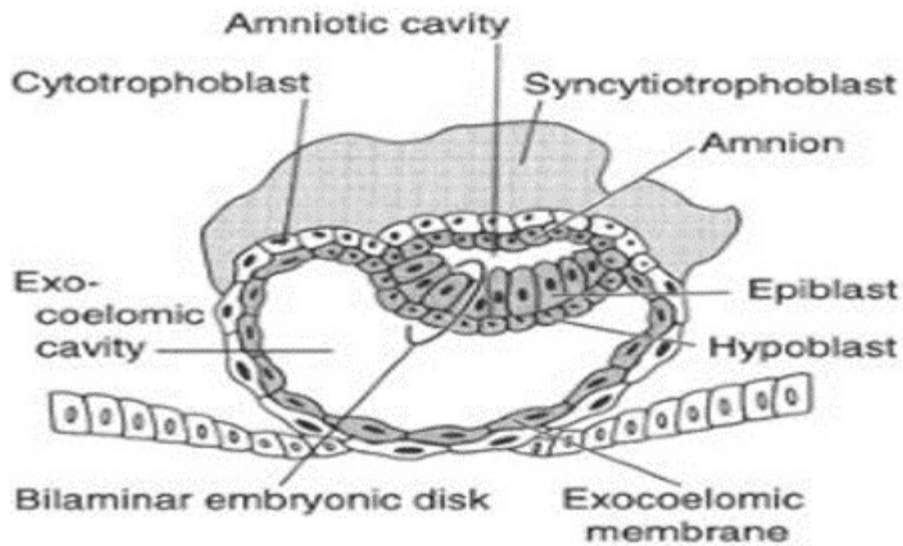
The second week of human development is concerned with the process of implantation of blastocyst and the differentiation of the blastocyst into early embryonic and placental forming structures. The second week of embryonic development occurs after the first week of embryonic development. It starts at day eight (8) and begins with the completion of implantation of blastocysts. In the process there is the formation of a bi laminar germ disc and lastly, development of extra embryonic structures from yolk sac. The duration of the second week of

embryonic development is from DAY 8 to DAY 13. These three major events include:

1. completion of implantation of blastocyst
2. formation of a bi laminar germ disc (epiblast and hypoblast)
3. development of extra embryonic structures (amniotic cavity, amnion, umbilical vesicle [yolk sac], connecting stalk, and chorionic sac)

### **DAY EIGHT (8) OF SECOND WEEK OF EMBRYONIC DEVELOPMENT**

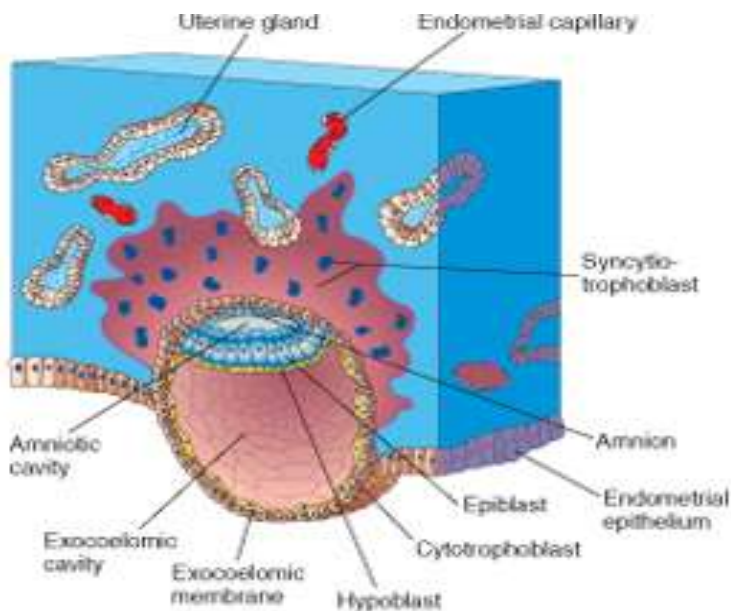
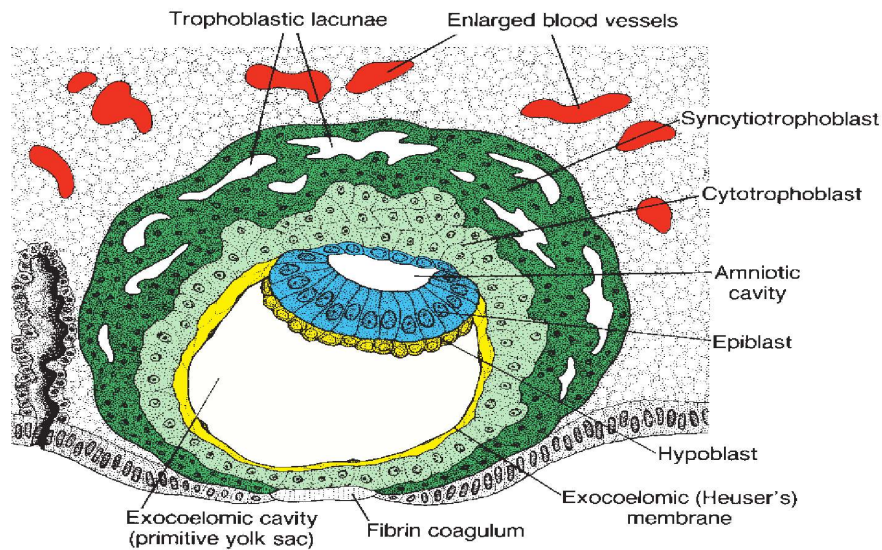
- At the eighth day of development, the blastocyst is partially embedded in the endometrium
- the syncytiotrophoblast continues its invasion of the endometrium,
- More cells in the cytotrophoblast divide and migrate into the syncytiotrophoblast region, where they fuse and lose their individual cell membranes
- Cells of the inner cell mass or embryoblast also differentiate into 2 layers:
  - the hypoblast layer, which is made up of small cuboidal cells, and it is adjacent(nearer) to the blastocyst cavity
  - the epiblast layer which is made up of high columnar cells, and it is adjacent to the amniotic cavity
    - The hypoblast and epiblast layers together form a flat ovoid shaped disc called the bilaminar embryonic disc
    - At the same time, a small cavity appears within the epiblast which enlarges to form the amniotic cavity
    - Epiblast cells adjacent to the cytotrophoblast are called amnioblasts
    - Amnioblasts together with the rest of the epiblast, line the amniotic cavity
    - The endometrium adjacent to the implantation site is edematous and highly vascular



51

## DAY NINE (9) OF SECOND WEEK OF HUMAN EMBRYONIC DEVELOPMENT

- The blastocyst is more deeply embedded in the endometrium, and the penetration defect in the surface epithelium is closed by a coagulum called fibrin
- Vacuoles appear at the region of the trophoblast and they fuse to form larger lacunae
- this phase of trophoblast development is Z
- this membrane lines the inner surface of the cytotrophoblast
- the exocoelomic (Heuser's) membrane together with the hypoblast forms the *lining of the exocoelomic cavity, or primitive yolk sac or primary umbilical vesicle*

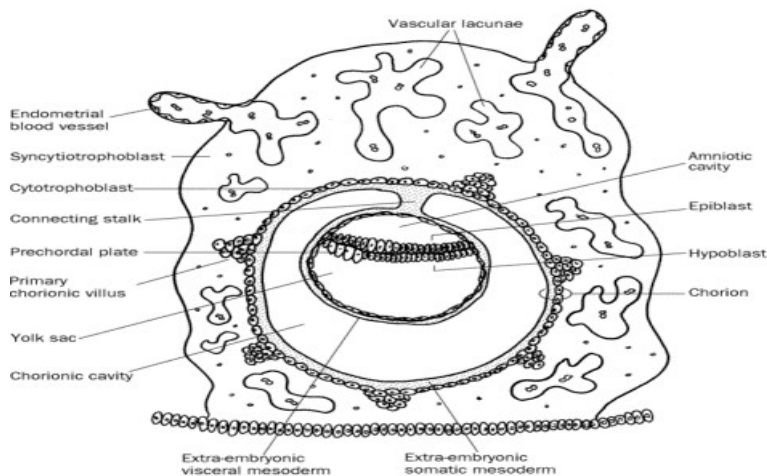
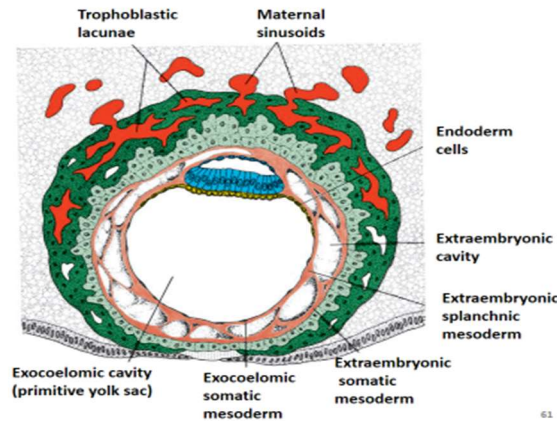


## DAYS ELEVEN- TWELVE (11-12) OF THE SECOND WEEK OF EMBRYONIC DEVELOPMENT

- The blastocyst is completely embedded in the endometrium,
- and the surface epithelium almost entirely covers the original defect in the uterine wall
- The blastocyst now produces a slight protrusion into the lumen of the uterus

- cells of the syncytiotrophoblast penetrate deeper into the stroma(tissue) and erode the endothelial lining of the endometrial capillaries
- These ruptured endometrial capillaries are called sinusoids
- The lacunae then begin to communicate with the sinusoids, and maternal blood enters the lacunar system
- The communication of the eroded endometrial capillaries with the lacunae establishes the primordial uteroplacental circulation
- When maternal blood flows into the lacunae, oxygen and nutritive substances are available to the embryo
- 
- a new population of cells appears between the inner surface of the cytotrophoblast and the outer surface of the exocoelomic cavity
- These cells which are derived from yolk sac cells form a fine, loose connective tissue called the extraembryonic mesoderm
- Soon, large cavities develop in the extraembryonic mesoderm, and when these become confluent, they form a new space known as the extraembryonic cavity or extraembryonic coelom
- This space surrounds the primitive yolk sac and amniotic cavity, except where the germ disc is connected to the trophoblast by the connecting stalk (which develops into the umbilical cord)
- The extraembryonic mesoderm lining the cytotrophoblast and amnion is called the extraembryonic somatic mesoderm
- extraembryonic somatic mesoderm also forms the connecting stalk
- the lining covering the yolk sac is known as the extraembryonic splanchnic mesoderm
- As the conceptus implants, the endometrial connective tissue cells undergo a transformation, called decidual reaction

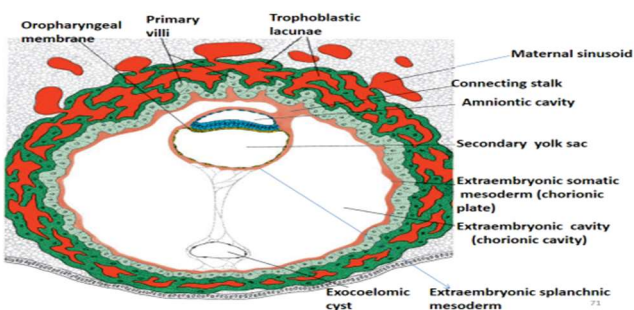
- During this transformation, the cells of the endometrium swell because of the accumulation of glycogen and lipid in their cytoplasm, and they are known as decidual cells
- The primary function of the decidual reaction is to provide nutrition for the early embryo and an immunologically privileged site for the conceptus



## DAY THIRTEEN (13) OF THE SECOND WEEK OF EMBRYONIC DEVELOPMENT

- The surface defect in the endometrium has been completely covered by the surface epithelium
- Occasionally bleeding occurs at the implantation site as a result of increased blood flow into the lacunar spaces

- *Cells of the cytotrophoblast proliferate locally and penetrate into the syncytiotrophoblast, forming cellular columns surrounded by syncytium*
- *Cellular columns with the syncytial covering are known as primary villi*
- *The primary yolk sac becomes reduced in size and is known as the secondary yolk sac*
- *This new cavity is known as the secondary yolk sac or definitive yolk sac or the secondary umbilical vesicle*
- In humans the yolk sac contains no yolk but is important for the transfer of nutrients between the fetus and mother
- This yolk sac is much smaller than the original exocoelomic cavity or primitive yolk sac
- During its formation, large portions of the exocoelomic cavity are pinched off to form exocoelomic cysts
- Exocoelomic cysts are often found in the extraembryonic cavity or chorionic cavity or extraembryonic coelom
- Meanwhile, the extraembryonic coelom expands and forms a large cavity called the chorionic cavity
- The extraembryonic mesoderm lining the inside of the cytotrophoblast is then known as the chorionic plate
- The only place where extraembryonic mesoderm traverses the chorionic cavity is in the connecting stalk
- With development of blood vessels, the connecting stalk becomes the umbilical cord



### **CLINICAL CORRELATE**

- The syncytiotrophoblast produces a hormone called the human chorionic gonadotrophin (hCG), which enters the maternal blood via lacunae keeps the corpus luteum secreting estrogens and progesterone
- hCG maintains the hormonal activity of the corpus luteum in the ovary during pregnancy
- hCG can be detected in maternal blood or urine as early as day 10 of pregnancy and is the basis for pregnancy tests
- Enough hCG is produced by the syncytiotrophoblast at the end of the second week to give a positive pregnancy test, even though the woman is probably unaware that she is pregnant.
- Extrauterine Implantation
  - Blastocysts may implant outside the uterus
  - These implantations result in ectopic pregnancies
  - 95% to 98% of ectopic implantations occur in the uterine tubes, most often in the ampulla and isthmus