

NAME: IGE TEMITOPE RACHEAL

MATRIC NUMBER: 18/MHS01/178

LEVEL: 200L

DEPARTMENT: MEDICINE AND SURGERY

**COLLEGE: MEDICINE AND HEALTH
SCIENCES**

COURSE: ANATOMY (EMBRYOLOGY)

LECTURER: DR. OGEDENGBE OLALEKAN

**ASSIGNMENT: DISCUSS THE SECOND WEEK
OF DEVELOPMENT**

DATE: 23/04/2020

2nd week of development

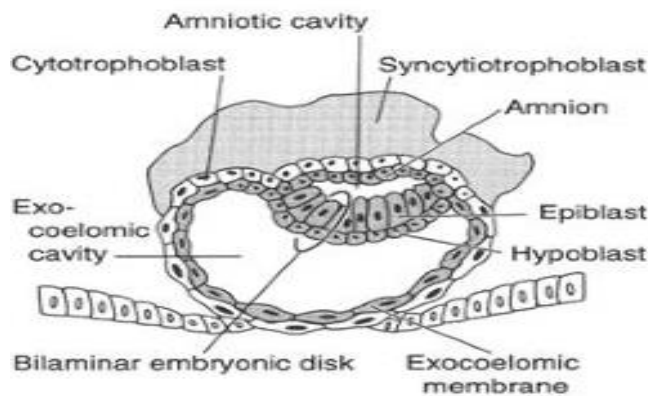
The following events take place during the 2nd week of development:

- I. Completion of implantation of the blastocyst
- II. Formation of bilaminar embryonic disc (epiblast and hypoblast)
- III. Formation of extraembryonic structures (amniotic cavity, amnion, umbilical vesicle [yolk sac], connecting stalk, and chorionic sac)

Day 8

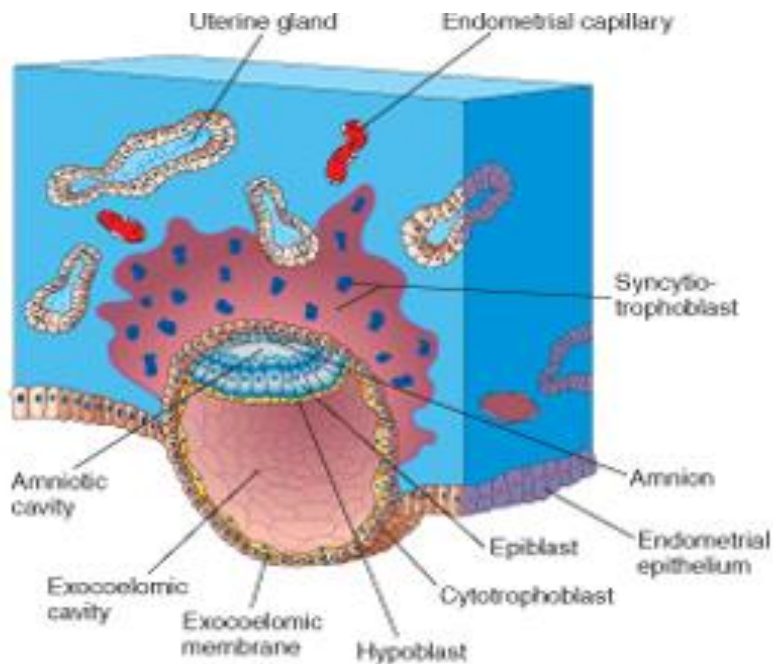
- At the eighth day of development, the blastocyst is partially (slowly) embedded in the endometrium
- the syncytiotrophoblast continues its invasion of the endometrium, thereby eroding endometrial blood vessels and endometrial glands
- More cells in the cytotrophoblast divide and migrate into the syncytiotrophoblast, where they fuse and lose their individual cell membranes
- Cells of the inner cell mass or embryoblast also differentiate into 2 layers:
 - I. the hypoblast layer, which is made up of small cuboidal cells, and it is adjacent(nearer) to the blastocyst cavity
 - II. the epiblast layer which is made up of high columnar cells, and it adjacent to the amniotic cavity
- The hypoblast and epiblast layers *together* form a flat ovoid shaped disc called the bilaminar embryonic disc
- At the same time, a small cavity appears within the epiblast which enlarges to form the amniotic cavity
- Epiblast cells adjacent to the cytotrophoblast are called amnioblasts
- Amnioblasts together with the rest of the epiblast, line the amniotic cavity

The endometrium adjacent to the implantation site is edematous and highly



Day 9

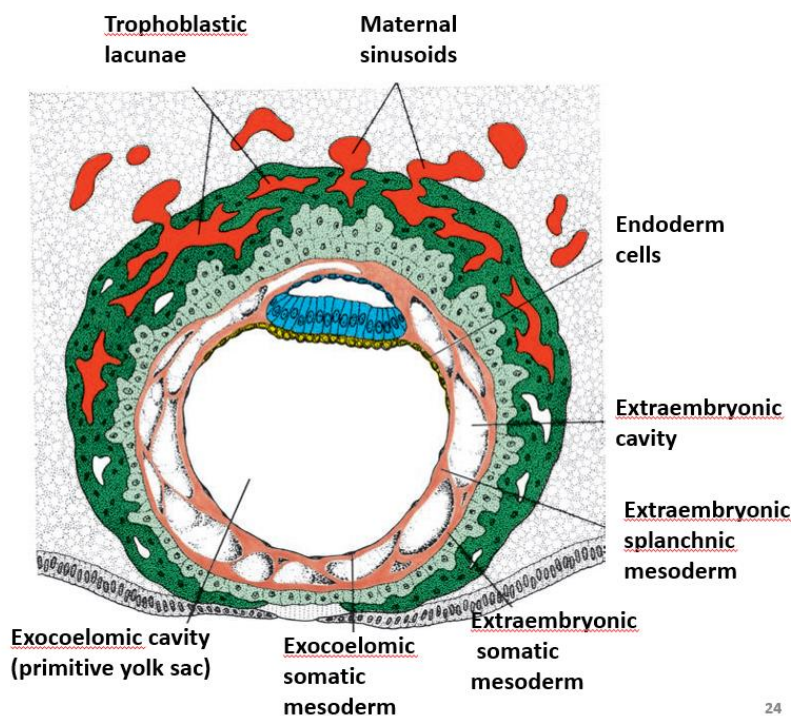
- The blastocyst is more deeply embedded in the endometrium, and the penetration defect in the surface epithelium is closed by a coagulum called **fibrin**
- Vacuoles appear at the region of the trophoblast and they fuse to form larger lacunae
- this phase of trophoblast development is known as the **lacunar stage**
- the cells of the hypoblast adjacent to the cytotrophoblast form a thin membrane called the **exocoelomic (Heuser's) membrane**
- this membrane lines the inner surface of the cytotrophoblast
- the **exocoelomic (Heuser's) membrane** together with the hypoblast forms the lining of the **exocoelomic cavity**, or **primitive yolk sac** or **primary umbilical vesicle**



- The blastocyst is completely embedded in the endometrium,
- and the surface epithelium almost entirely covers the original defect in the uterine wall
- The blastocyst now produces a slight protrusion into the lumen of

the uterus

- cells of the syncytiotrophoblast penetrate deeper into the stroma(tissue) and erode the endothelial lining of the endometrial capillaries
- These ruptured endometrial capillaries are called **sinusoids**
- The lacunae then begin to communicate with the sinusoids, and maternal blood enters the lacunar system
- The communication of the eroded endometrial capillaries with the lacunae establishes the **primordial uteroplacental circulation**
- When maternal blood flows into the lacunae, oxygen and nutritive substances are available to the embryo



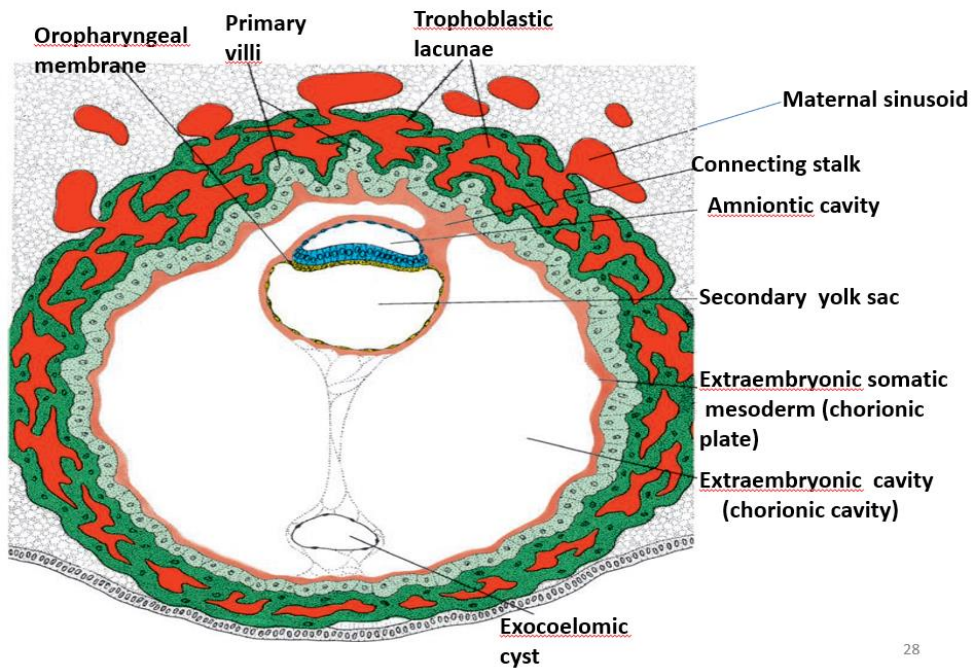
24

- a new population of cells appears between the inner surface of the cytotrophoblast and the outer surface of the exocoelomic cavity
- These cells which are derived from yolk sac cells form a fine, loose connective tissue called the **extraembryonic mesoderm**
- Soon, large cavities develop in the extraembryonic mesoderm, and when these become confluent, they form a new space known as the **extraembryonic cavity, or chorionic cavity or extraembryonic coelom**

- This space surrounds the primitive yolk sac and amniotic cavity, except where the germ disc is connected to the trophoblast by the connecting stalk
- The extraembryonic mesoderm lining the cytotrophoblast and amnion is called the **extraembryonic somatic mesoderm**
- the lining covering the yolk sac is known as the **extraembryonic splanchnic mesoderm**
- As the conceptus implants, the endometrial connective tissue cells undergo a transformation, called **decidual reaction**
- During this transformation, the cells of the endometrium swell because of the accumulation of glycogen and lipid in their cytoplasm, and they are known as **decidual cells**
- The primary function of the decidual reaction is to provide nutrition for the early embryo and an immunologically privileged site for the conceptus

13th day of development

- The surface defect in the endometrium has been completely covered by the surface epithelium
- Occasionally bleeding occurs at the implantation site as a result of increased blood flow into the lacunar spaces
- Cells of the cytotrophoblast proliferate locally and penetrate into the syncytiotrophoblast, forming cellular columns surrounded by syncytium
- Cellular columns with the syncytial covering are known as **primary villi**
- In the meantime, the hypoblast produces additional cells that migrate along the inside of the exocoelomic membrane
- These cells proliferate and gradually form a new cavity within the exocoelomic cavity
- This new cavity is known as the **secondary yolk sac** or **definitive yolk sac** or the **secondary umbilical vesicle**
- This yolk sac is much smaller than the original exocoelomic cavity or primitive yolk sac
- During its formation, large portions of the exocoelomic cavity are pinched off to form **exocoelomic cysts**



28

- **Exocoelomic cysts** are often found in the extraembryonic cavity or chorionic cavity or extraembryonic coelom
- Meanwhile, the extraembryonic coelom expands and forms a large cavity, the **chorionic cavity**
- The extraembryonic mesoderm lining the inside of the cytotrophoblast is then known as the chorionic plate
- The only place where extraembryonic mesoderm traverses the chorionic cavity is in the **connecting stalk**
- With development of blood vessels, the connecting stalk becomes the **umbilical cord**