

ARELOEGBE, Stephanie Esosa

18/MHS05/004

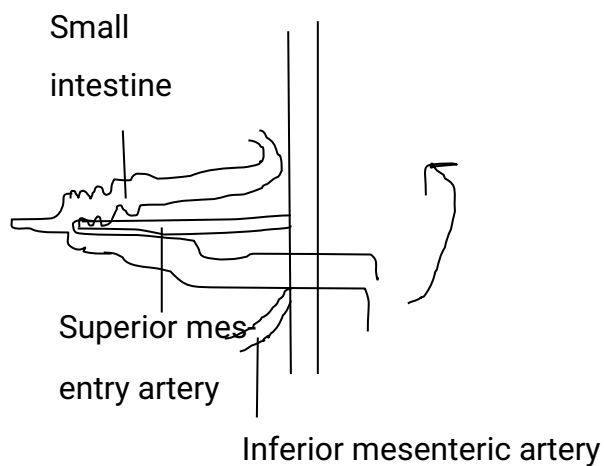
PHYSIOLOGY

ORGANOGENESIS

ANA 206

ROTATION OF THE INTESTINE

While the midgut loop is still in the umbilical cord, it rotates counterclockwise around the axis of the superior mesenteric artery.



This brings the cranial limb (small intestine) of the loop to the right and the caudal limb (large intestine) to the left. During rotation, the cranial limb elongates and forms intestinal loops (e.g., the primordial of the jejunum and ileum).

