

NAME: EMMANUEL COLLINS DANIEL **MAT NUMBER:** 18/MHS01/121

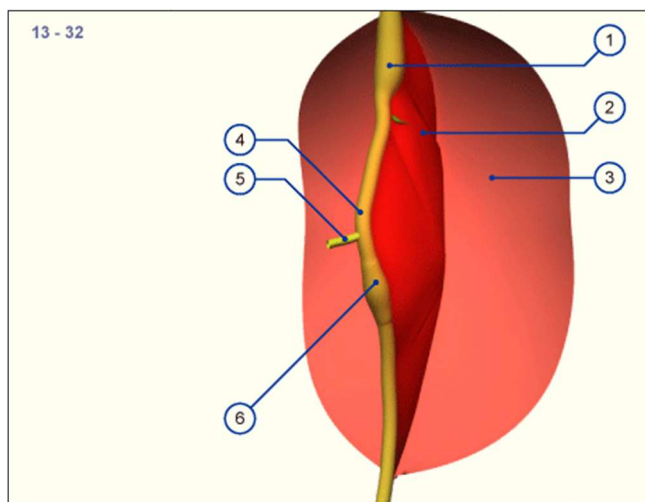
DEPARTMENT: ANATOMY

COURSE: EMBRYOLOGY **COURSE CODE:** ANA 206

Q: Discuss the rotation of the intestine

A) In 32 days, the midgut begins to extend into the umbilical coelom and forms the umbilical loop, whereby initially from the apex only a wide connection to the umbilical vesicle exists. In the further development this junction becomes constricted to become the omphalomesenteric duct. Mostly it is later obliterated, but can also partially remain as a Meckel's diverticulum. In the beginning the umbilical loop is positioned sagittally

32 days

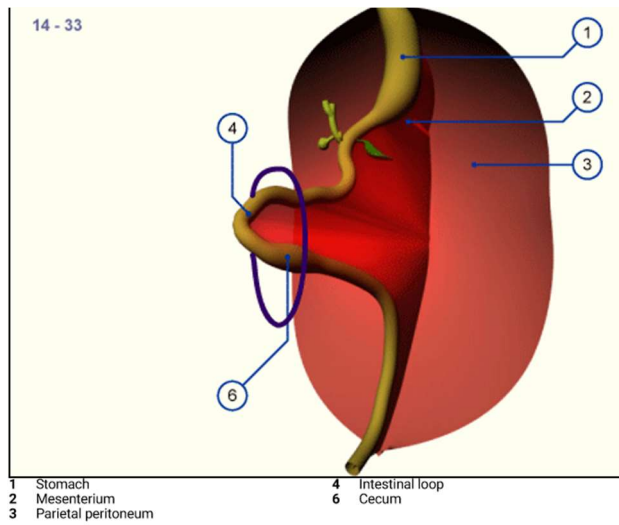


- 1 Stomach 4 Intestinal loop
- 2 Mesenterium 3 Parietal peritoneum
- 5 Omphalomesenteric duct 6 Cecum

The intestinal tube becomes enwrapped by the visceral peritoneum that connects it to the posterior body wall forming the dorsal mesenterium (red surface). In this stage the intestinal tube is almost straight and is connected to the umbilical vesicle by the omphalomesenteric duct.

B) Only when the umbilical loop lengthens and grows into the umbilical coelom does it experience a rotation of 90 degrees in a clockwise direction as seen from the embryo. The cranial pedicle comes to lie to the right and the caudal to the left 33 days, The umbilical loop now has a horizontal position. Through the craniocaudal growth gradient, the cranial pedicle forms first through lengthening of several loops in the umbilical coelom.

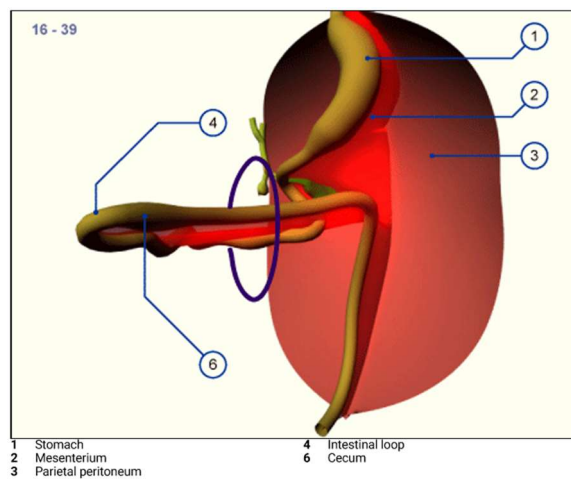
33days



The navel opening is schematically indicated by the blue ring. The developing intestines invade the abdominal space, gliding into it.

C) The developing umbilical loop extends further into the umbilical coelom because there is no more room for it within the embryo's abdominal cavity. It is the time of the strongest flexion of the embryo. Very soon a thickening in the region of the caudal pedicle of the intestinal tube is also to be seen: the cecum. Visually, it becomes an important fixed point for purposes of orientation.

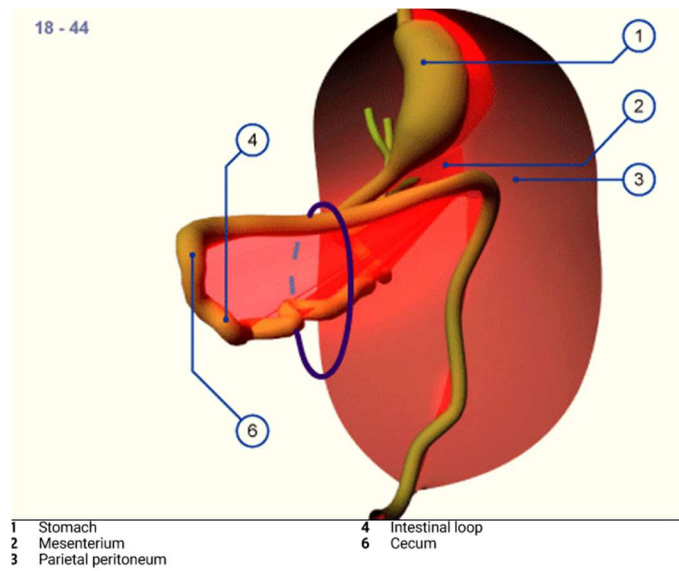
39 days



The entire intestinal loop has relocated in the umbilical coelom due to the limited space conditions in the abdominal cavity. The intestinal loop now has a horizontal orientation and the lengthening tube has formed several loops in the cranial pedicle. The caudal part is still straight.

D) As development proceeds the intestinal loop turns further around its own axis. 44 days, the extension of the intestinal loop into the umbilical coelom has reached its maximum. This physiologic navel hernia remains in existence up to the 9th week of pregnancy. (Omphalocele / umbilical hernia)

44days

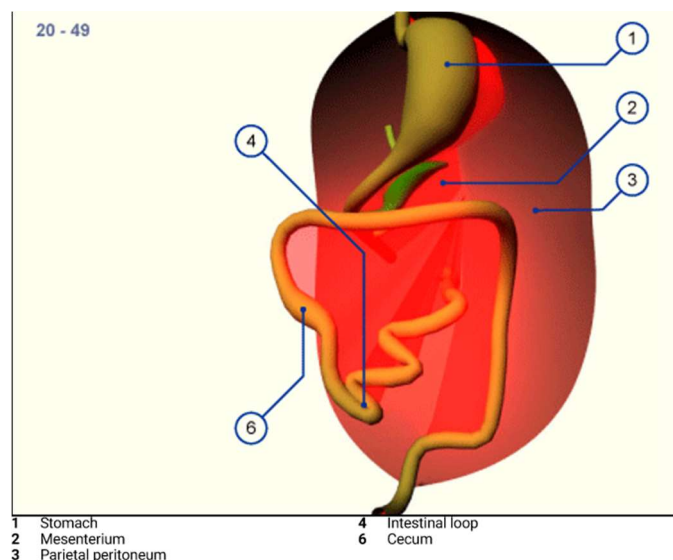


The largest part of the intestinal loop lies in the umbilical coelom and several loops have formed through the lengthening in the cranial, small intestine region.

E) At first, the loops of the small intestine return into the abdominal cavity and come to lie in the left half surrounded by the horizontal and descending part of the colon that never left the abdominal cavity. The rotation now amounts to more than 180 degrees and the colon is also shifted more and more into the abdominal space. The

repositioning of the physiologic umbilical hernia is facilitated by the righting of the embryo's body.

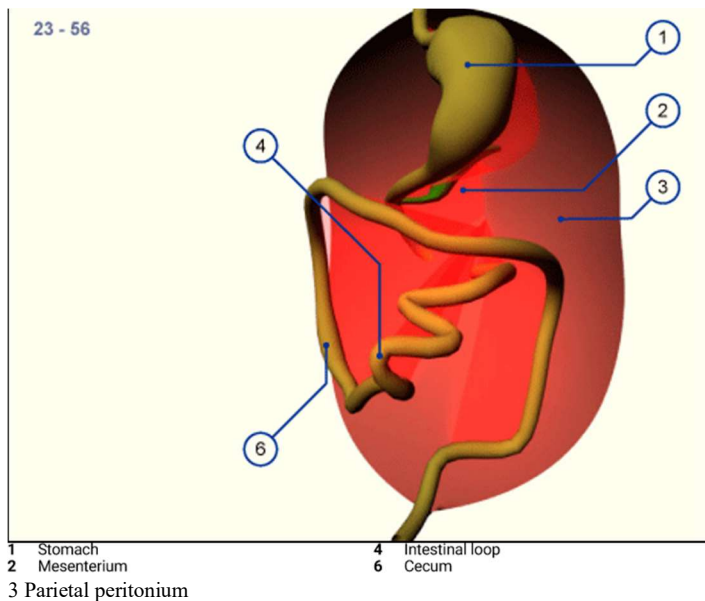
49days



With the return of the intestines into the abdominal cavity the small intestine is moved to the left side and the cecum and the ascending part of the large intestine to the right. Initially the cecum may possibly be found in the upper right quadrant (elevated cecum).

F) Thus, after the reintegration of the intestinal loops into the abdominal cavity from the physiologic umbilical hernia, the derivatives of the originally caudal pedicle occupies the upper and ventral part of the abdominal cavity. At the end of the embryonic period this part migrates downwards into the iliac fossa, whereby an additional rotation occurs. The whole rotation of the intestines thus amounts to approximately 270 degrees. As a consequence, the mesenterium also turns with it and in its insertion it crosses over the inferior part of the duodenum. (Malrotation and congenital high cecum).

Intestinal rotation 56 days



As a rule the cecum grows caudally and comes to lie in the right iliac fossa. Through rotation of the whole small intestine of more than 270 degrees the mesenterium also rotates thereby and moves off from the posterior wall over the inferior part of the duodenum to the small intestine.