

**NAME: ODIWAMKPA UCHENNA**  
**MATRIC NUMBER:17/MHS01/228**  
**COURSE: HISTOLOGY OF SPECIAL SENSES AND**  
**NEUROHISTOLOGY**  
**DEPARTMENT: MEDICINE AND SURGERY 300L**

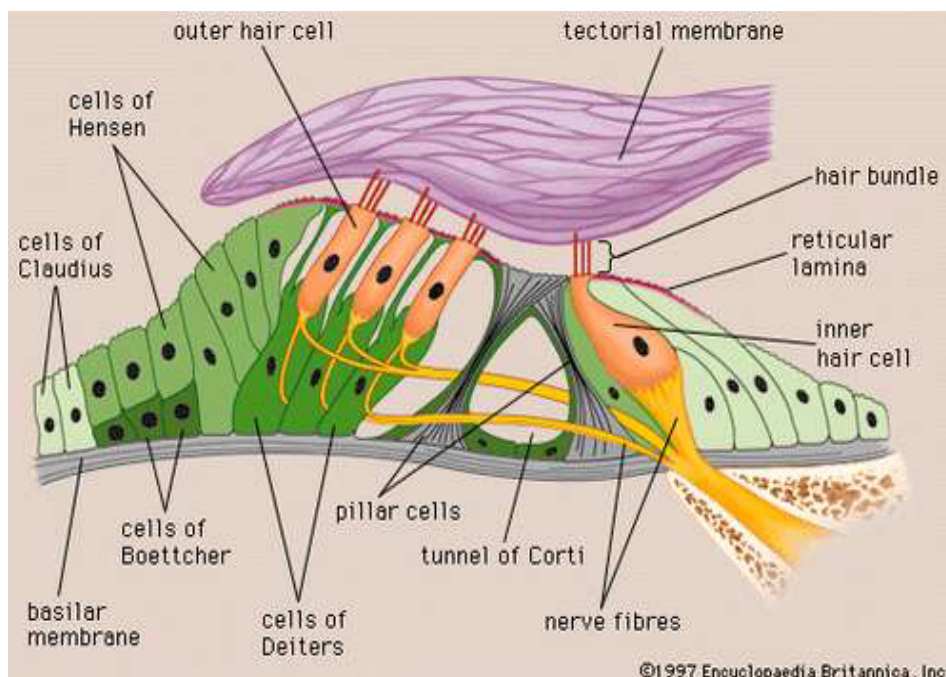
**QUESTION**

**1) With the aid of a diagram write an essay on the histology of an Organ of Corti**

**ANSWER**

**ORGAN OF CORTI**

Arranged on the surface of the basilar membrane are orderly rows of the sensory hair cells, which generate nerve impulses in response to sound vibrations. Together with their supporting cells they form a complex neuroepithelium called the basilar papilla, or organ of Corti. The organ of Corti is named after Italian anatomist Alfonso Corti, who first described it in 1851. Viewed in cross section, the most striking feature of the organ of Corti is the arch, or tunnel, of Corti, formed by two rows of pillar cells, or rods. The pillar cells furnish the major support of this structure. They separate a single row of larger, pear-shaped inner hair cells from three or more rows of smaller, cylindrical outer hair cells. The inner hair cells are supported and enclosed by the inner phalangeal cells, which rest on the thin outer portion, called the tympanic lip, of the spiral limbus. On the inner side of the inner hair cells and the cells that support them is a curved furrow called the inner sulcus. This is lined with more or less undifferentiated cuboidal cells.



## DIAGRAM OF THE ORGAN OF CORTI

Each outer hair cell is supported by a phalangeal cell of Deiters, or supporting cell, which holds the base of the hair cell in a cup-shaped depression. From each Deiters' cell a projection extends upward to the stiff membrane, the reticular lamina, that covers the organ of Corti. The top of the hair cell is firmly held by the lamina, but the body is suspended in fluid that fills the space of Nuel and the tunnel of Corti. Although this fluid is sometimes referred to as cortilymph, its composition is thought to be similar, if not identical, to that of the perilymph. Beyond the hair cells and the Deiters' cells are three other types of epithelial cells, usually called the cells of Hensen, Claudius, and Boettcher, after the 19th-century anatomists who first described them. Their function has not been established, but they are assumed to help in maintaining the composition of the endolymph by ion transport and absorptive activity.

Each hair cell has a cytoskeleton composed of filaments of the protein actin, which imparts stiffness to structures in which it is found. The hair cell is capped by a dense cuticular plate, composed of actin filaments, which bears a tuft of stiffly erect stereocilia, also containing actin, of graded lengths arranged in a staircase pattern. This so-called hair bundle has rootlets anchored firmly in the cuticular plate. On the top of the inner hair cells 40 to 60 stereocilia are arranged in two or more irregularly parallel rows. On the outer hair cells approximately 100 stereocilia form a W pattern. At the notch of the W the plate is incomplete, with only a thin cell membrane taking its place. Beneath the membrane is the basal body of a KINOCILIUM, although no motile ciliary (hairlike) portion is present as is the case on the hair cells of the vestibular system.

The stereocilia are about 3 to 5  $\mu\text{m}$  in length. The longest make contact with but do not penetrate the tectorial membrane. This membrane is an acellular gelatinous structure that covers the top of the spiral limbus as a thin fibrillar layer, then becomes thicker as it extends outward over the inner sulcus and the reticular lamina. Its fibrils extend radially and somewhat obliquely to end at its lateral border, just above the junction of the reticular lamina and the cells of Hensen. In the upper turns of the cochlea, the margin of the membrane ends in fingerlike projections that make contact with the stereocilia of the outermost hair cells.

The myelin-ensheathed fibres of the vestibulocochlear nerve fan out in spiral fashion from the modiolus to pass into the channel near the root of

the osseous spiral lamina, called the canal of Rosenthal. The bipolar cell bodies of these neurons constitute the spiral ganglion. Beyond the ganglion their distal processes extend radially outward in the bony lamina beneath the limbus to pass through an array of small pores directly under the inner hair cells, called the habenula perforata. Here the fibres abruptly lose their multilayered coats of myelin and continue as thin, naked, unmyelinated fibres into the organ of Corti. Some fibres form a longitudinally directed bundle running beneath the inner hair cells and another bundle just inside the tunnel, above the feet of the inner pillar cells. The majority of the fibres (some 95 percent in the human ear) end on the inner hair cells. The remainder cross the tunnel to form longitudinal bundles beneath the rows of the outer hair cells on which they eventually terminate.

The endings of the nerve fibres beneath the hair cells are of two distinct types. The larger and more numerous endings contain many minute vesicles, or liquid-filled sacs, containing neurotransmitters, which mediate impulse transmission at neural junctions. These endings belong to a special bundle of nerve fibres that arise in the brainstem and constitute an efferent system, or feedback loop, to the cochlea. The smaller and less numerous endings contain few vesicles or other cell structures. They are the terminations of the afferent fibres of the cochlear nerve, which transmit impulses from the hair cells to the brainstem.

The total number of outer hair cells in the cochlea has been estimated at 12,000 and the number of inner hair cells at 3,500. Although there are about 30,000 fibres in the cochlear nerve, there is considerable overlap in the innervation of the outer hair cells. A single fibre may supply endings to many hair cells, which thus share a "party line." Furthermore, a single hair cell may receive nerve endings from many fibres. The actual distribution of nerve fibres in the organ of Corti has not been worked out in detail, but it is known that the inner hair cells receive the majority of afferent fibre endings without the overlapping and sharing of fibres that are characteristic of the outer hair cells.

Viewed from above, the organ of Corti with its covering, the reticular lamina, forms a well-defined mosaic pattern. In humans the arrangement of the outer hair cells in the basal turn of the cochlea is quite regular, with three distinct and orderly rows; but in the higher turns of the cochlea the arrangement becomes slightly irregular, as scattered cells form fourth or fifth rows. The spaces between the outer hair cells are filled by oddly shaped extensions (phalangeal plates) of the supporting cells. The

double row of head plates of the inner and outer pillar cells cover the tunnel and separate the inner from the outer hair cells. The reticular lamina extends from the inner border cells near the inner sulcus to the Hensen cells but does not include either of these cell groups. When a hair cell degenerates and disappears as a result of aging, disease, or noise-induced injury, its place is quickly covered by the adjacent phalangeal plates, which expand to form an easily recognized “scar.”