

## NEUROHISTOLOGY ASSIGNMENT

NAME: SANYA OLUSOLA AKINNIYI

MATRIC NO: 19/MHS01/448

DEPARTMENT: MEDICINE AND SURGERY

LEVEL: 300

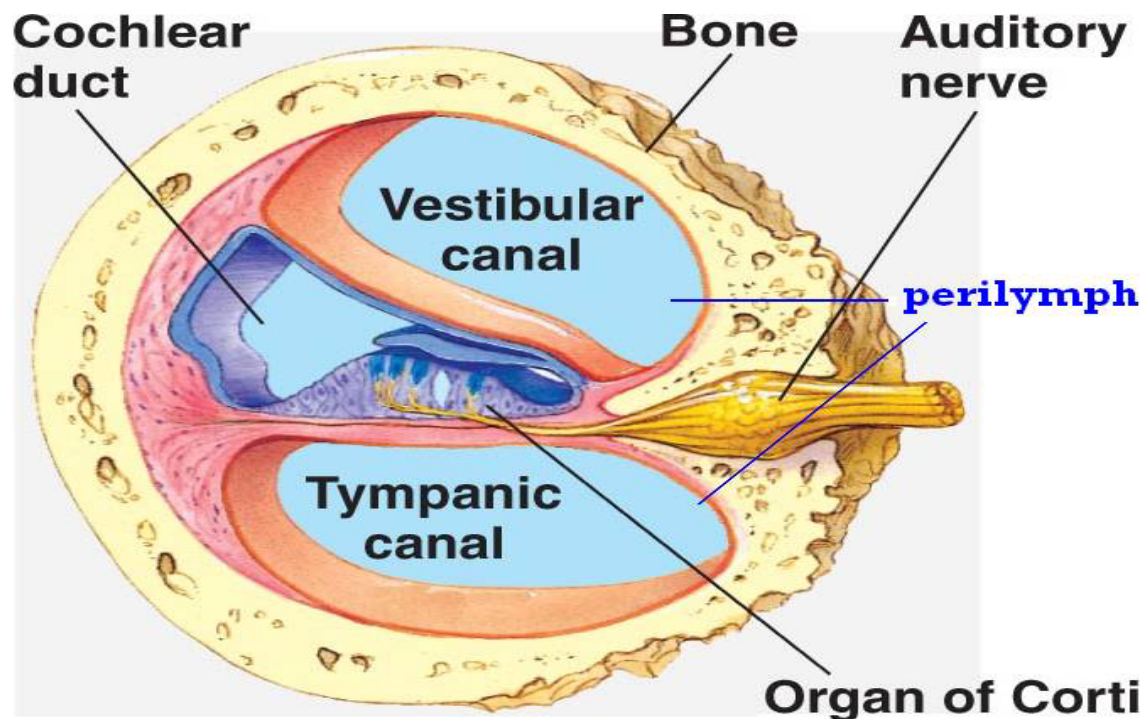
QUESTION:

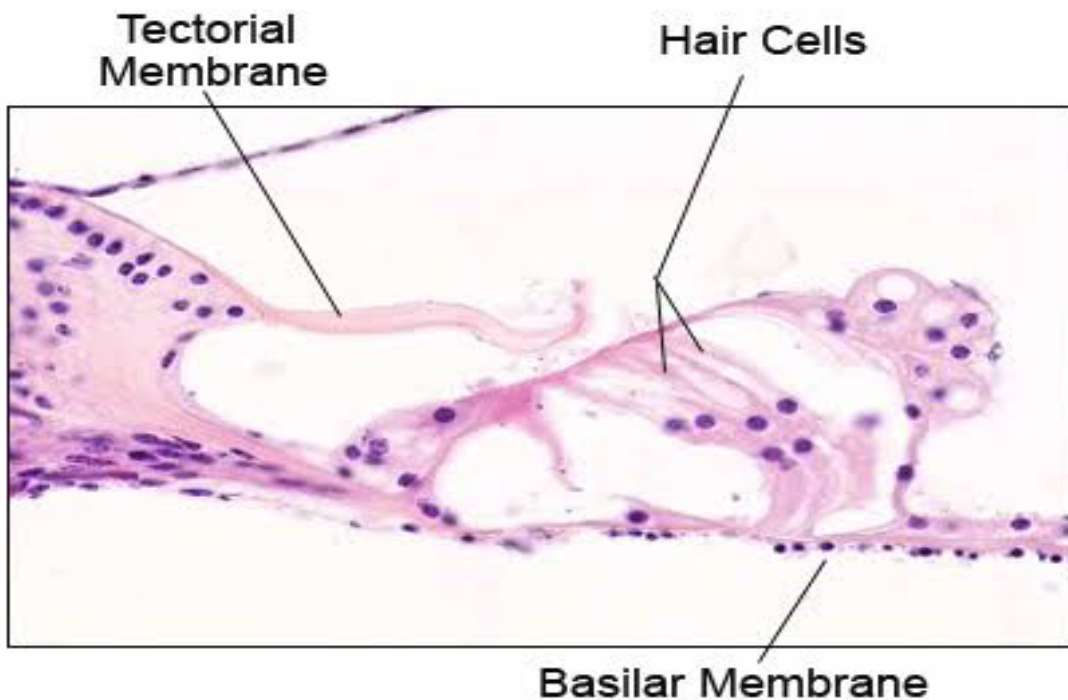
With the aid of a diagram, write an essay on the histology of an ORGAN OF CORTI

### HISTOLOGY OF THE ORGAN OF CORTI

The organ of Corti is also referred to as the spiral organ of Corti.

It is so called because (like other structures in the cochlea) it extends in a spiral manner through the turns of the cochlea.





In sections, it is seen to be placed on the basilar membrane and to be made up of epithelial cells that are arranged in a complicated manner.

The cells are divisible into the true receptor cells or hair cells, and supporting elements which are given different names depending on their location.

The cells of the spiral organ are covered from above by a gelatinous mass called the membrana tectoria.

The cells of the spiral organ enclose a triangular cavity called the tunnel of Corti (or cuniculum internum).

The base of the tunnel lies over the basilar membrane.

It has a sloping inner wall that is formed by internal rod cells; and a sloping outer wall that is formed by external rod cells.

To the internal side of the inner rod cells there is a single row of inner hair cells.

The inner hair cell is supported by tall cells lining the tympanic lip of the internal spiral sulcus.

On the outer side of each external rod cell there are three or four outer hair cells.

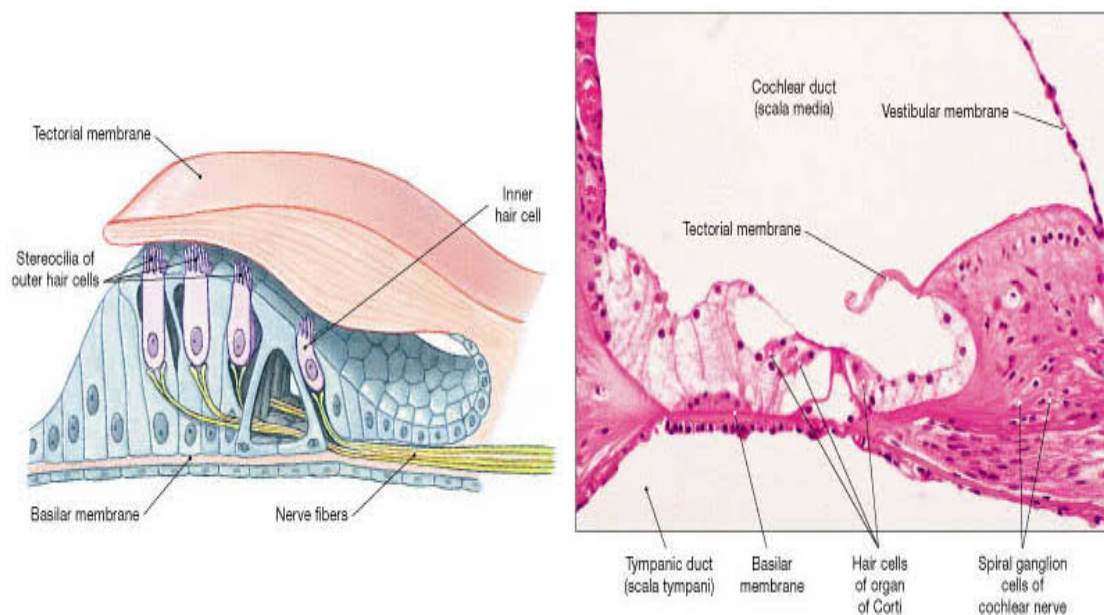
The outer hair cells do not lie directly on the basilar membrane, but are supported by the phalangeal cells (of Deiters) which rest on the basilar membrane.

To the outer side of the outer hair cells and the phalangeal cells, there are tall supporting cells (cells of Hensen). Still more externally the outer spiral sulcus is lined by cubical cells (cells of Claudius).

A narrow space the cuniculum externum intervenes between the outermost hair cells and the cells of Hensen.

A third space, the cuniculum medium (or space of Nuel) lies between the outer rod cell and the outer hair cells.

The spaces are filled with perilymph (or cortilymph).



(e) Organ of Corti

## Rod Cells

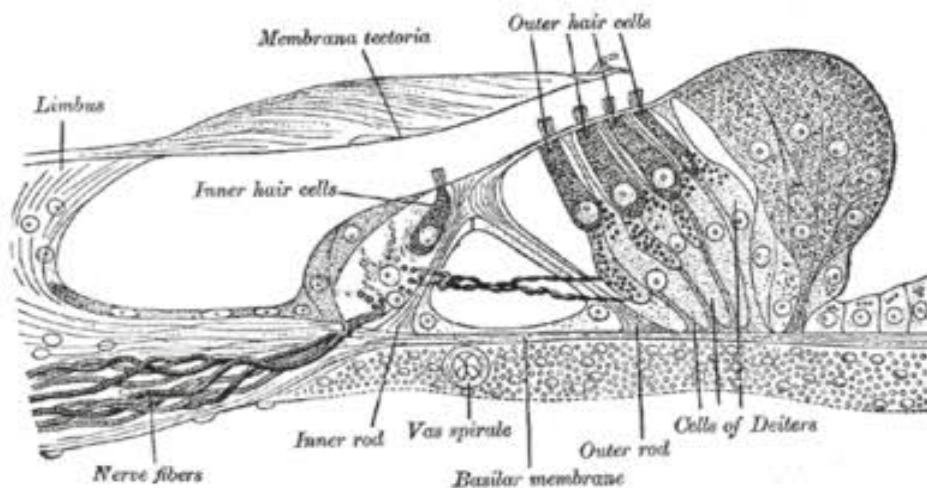
Each rod cell (or pillar cell) has a broad base (or foot plate, or crus) that rests on the basilar membrane; an elongated middle part (rod or scapus); and an expanded upper end called the head or caput.

The bases of the rod cells are greatly expanded and contain their nuclei. The bases of the inner and outer rod cells meet each other forming the base of the tunnel of Corti.

The heads of these cells also meet at the apex of the tunnel. Here a convex prominence on the head of the outer rod cell fits into a concavity on the head of the inner rod cell.

The uppermost parts of the heads are expanded into horizontal plates called the phalangeal processes.

These processes join similar processes of neighbouring cells to form a continuous membrane called the reticular lamina.



## The Hair Cells

The hair cells are so called because their free 'upper' or apical ends bear a number of 'hair'.

The hair are really stereocilia. Each cell is columnar or piriform. The hair

cells are distinctly shorter than the rod cells.

Their apices are at the level of the reticular lamina. Their lower ends (or bases) do not reach the basilar membrane.

They rest on phalangeal cells. The plasma membrane at the base of each hair cell forms numerous synaptic contacts with the terminations of the peripheral processes of neurons in the spiral ganglion.

Some efferent terminals are also present.

The apical surface of each hair cell is thickened to form a cuticular plate the edges of which are attached to neighbouring cells.

With the Electron Microscope (EM), the 'hair' of hair cells are seen to be similar to microvilli.

Each hair has a covering of plasma membrane within which there is a core of microfilaments.

Each hair is cylindrical over most of its length, but it is much narrowed at its base. The hair can, therefore, bend easily at this site.

The hair on each hair cell are arranged in a definite manner. When viewed from 'above' they are seen to be arranged in the form of the letter 'V' or 'U'. Each limb of the 'V' has three rows of hairs.

The hairs in the three rows are of unequal height being tallest in the 'outer' row, intermediate in the middle row, and shortest in the 'inner' row.

The 'V' formed by the hairs of various hair cells are all in alignment, the apex of the 'V' pointing towards the 'outer' wall of the cochlear canal.

At the point corresponding to the apex of the 'V' there is a centriole lying just under the apical cell membrane, but a true kinocilium is not present (unlike hair cells of ampullary crests).

The above description applies to both inner and outer hair cells.

Differences between the two are as follows:

The inner hair cells are piriform (flask shaped) and relatively short; while the outer hair cells are cylindrical and longer.

The lower end of each outer hair cell fits into a depression on the upper end of a phalangeal cell, but the inner hair cells do not have such a relationship.

The 'hair' of the outer hair cells are somewhat longer and more slender than those on inner hair cells.

They are arranged as a shallow 'U' rather than a 'V'.

Occasionally, the outer hair cells may have more than three rows of hair, and the rows may assume the shape of a 'W' (instead of a 'V').

But in all hair cells, the apex of the 'V' (formed by the rows of hair)

points towards the 'outer' wall of the cochlear canal (i.e., away from the modiolus).

The direction of the 'V' is sometimes described in relation to the tunnel of Corti.

In the inner hair cells the 'V' points towards the tunnel, while in the case of the outer cells it points away from the tunnel.

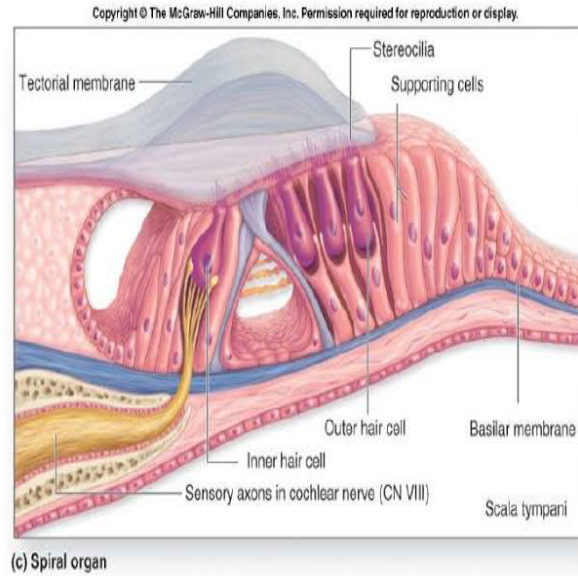
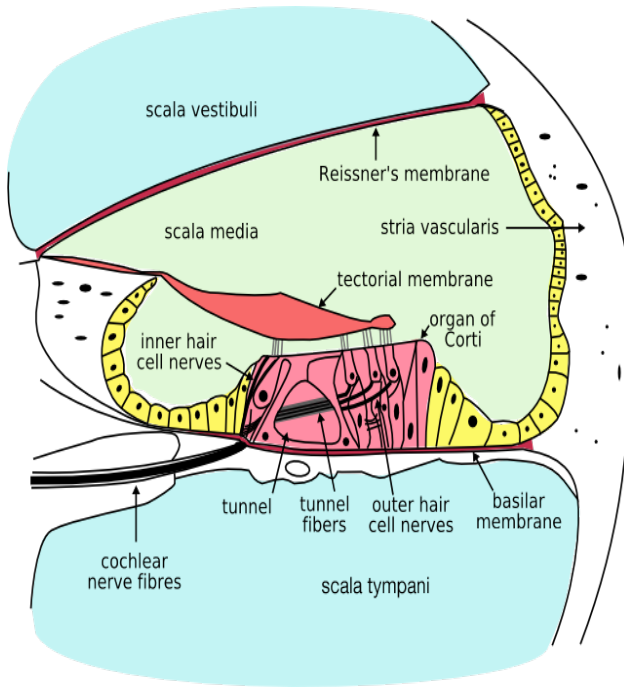
The direction of the 'V' is of functional importance. Like hair cells of the maculae and cristae, those of the cochlea are polarized.

Bending of stereocilia towards the apex of the 'V' causes depolarisation, while the reverse causes hyperpolarisation.

Ionic gradients associated with depolarisation and hyperpolarisation are maintained because apices of hair cells and surrounding cells are tightly



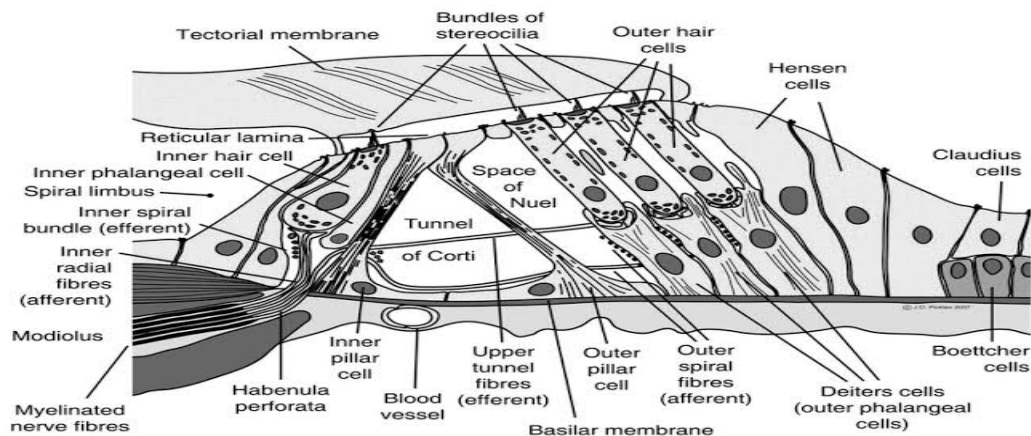
sealed by occluding junctions.



## The Outer Phalangeal Cells and Reticular Lamina

These are the cells that support the outer hair cells. They lie lateral to the outer rod cells.

Their bases rest on the basilar membrane. Their apical parts have a complicated configuration.



The greater part of the apex forms a cup-like depression into which the base of an outer hair cell fits.

Arising from one side (of the apical part) of the cell there is a thin rod-like phalangeal process.

This process passes 'upwards', in the interval between hair cells, to reach the level of the apices of hair cells.

Here the phalangeal process expands to form a transverse plate called the phalanx.

The edges of the phalanges of adjoining phalangeal cells unite with each other to form a membrane called the reticular lamina.

(The reticular lamina also receives contributions from the heads of hair cells).

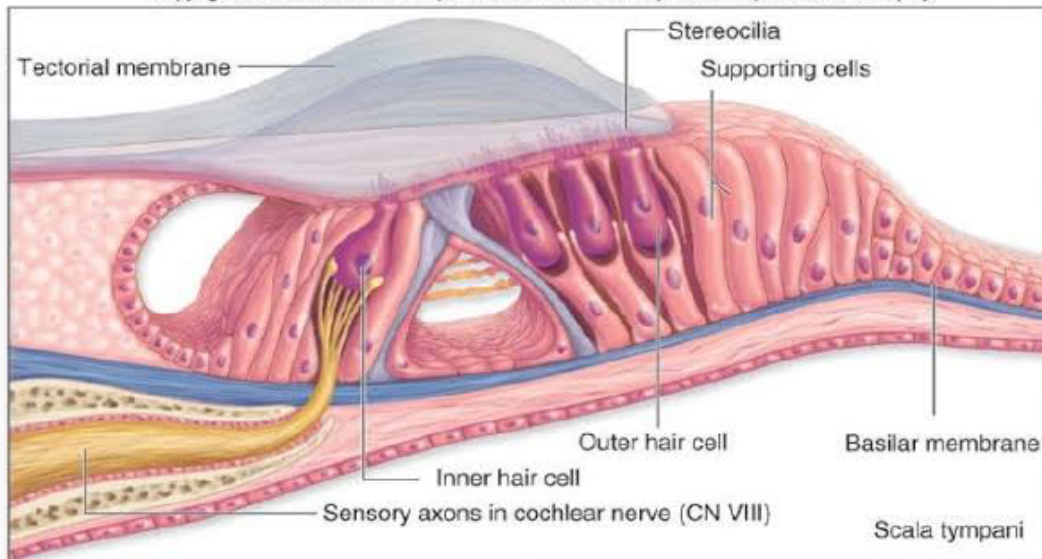
The apices of hair cells protrude through apertures in this lamina.

The cell edges forming the reticular lamina contain bundles of microtubules embedded in dense cytoplasm.

Adjacent cell margins are united by desmosomes, occluding junctions and gap junctions.

The reticular lamina forms a barrier impermeable to ions except through the cell membranes. It also forms a rigid support between the apical parts of hair cells thus ensuring that the hair cells rub against the membrana tectoria when the basilar membrane vibrates.





(c) Spiral organ

## The Membrana Tectoria

The membrana tectoria lies over the internal spiral sulcus and over the hair cells of the spiral organ.

It consists of delicate fibres embedded in a gelatinous matrix. This material is said to be secreted by cells lining the vestibular lip of the limbus lamina spiralis.

A narrow gap separates the membrana tectoria from the reticular lamina. The stereocilia of outer hair cells are in contact with the membrana tectoria.