

**NAME: AWOSAN SAMUEL OLUWAGBENGA**

**MATRIC NUMBER: 17/MHS01/071**

**MEDICINE AND SURGERY**

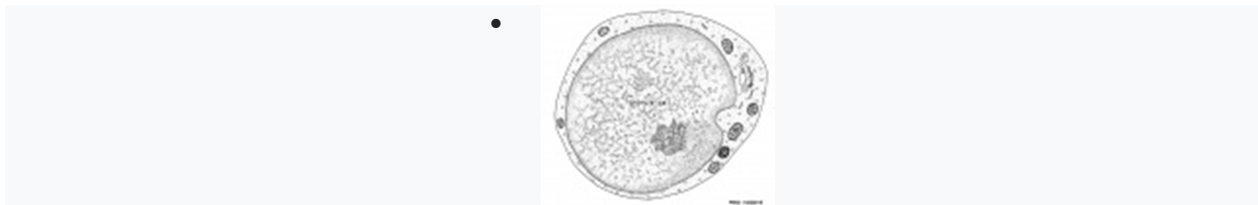
**ASSIGNMENT**

**Write a concise review on the developmental genetics of the cerebellum and highlight the genetic bases of known cerebellar disorders**

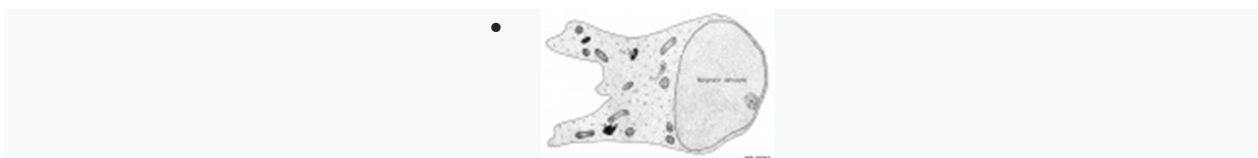## Cerebellar Cells

---

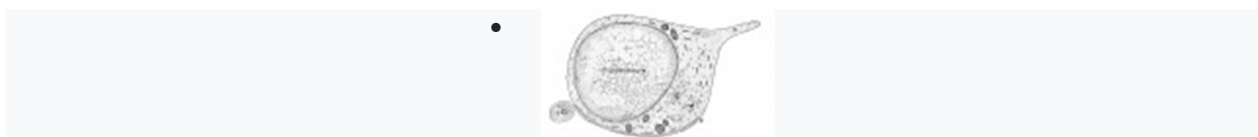
These drawings of cerebellar cells were based upon electron micrograph images from the rat cerebellum.



granule cell



Bergmann astrocyte



oligodendrocyte

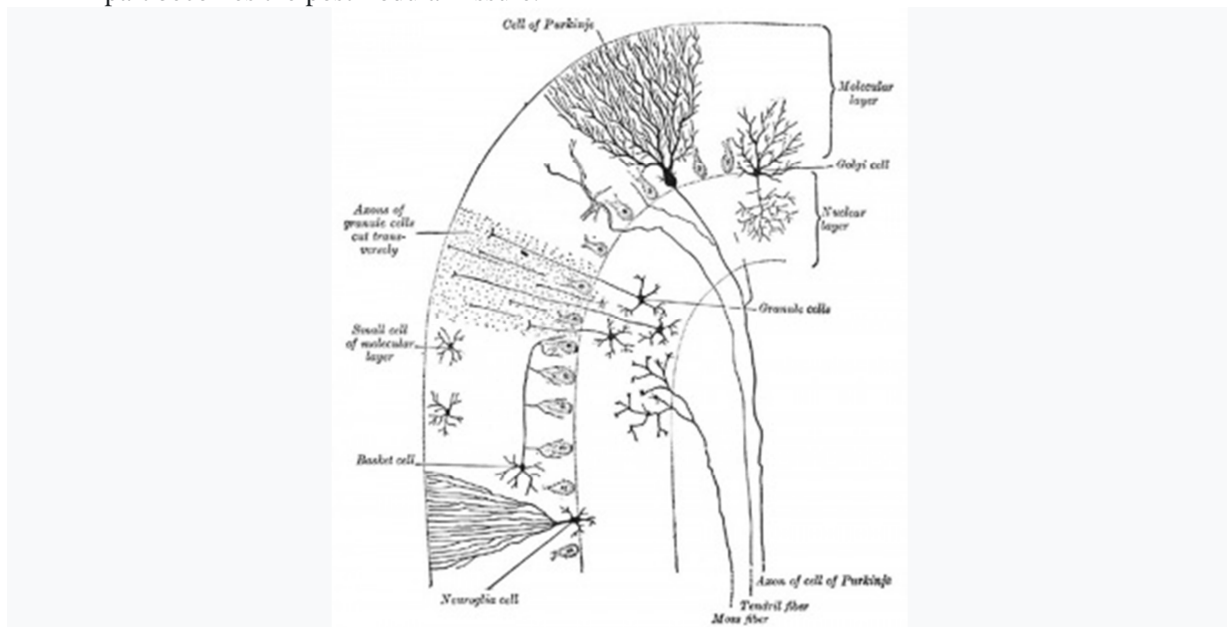
Purkinje Cell

**Search:** [Purkinje cell Development](#)

Historic Description

Gray H. [Anatomy of the human body](#). (1918) Philadelphia: Lea & Febiger.

"The cerebellum is developed in the roof of the anterior part of the hind-brain (Figs. 649 to 654). The alar laminæ of this region become thickened to form two lateral plates which soon fuse in the middle line and produce a thick lamina which roofs in the upper part of the cavity of the hind-brain vesicle; this constitutes the rudiment of the cerebellum, the outer surface of which is originally smooth and convex. The fissures of the cerebellum appear first in the vermis and floccular region, and traces of them are found during the third month; the fissures on the cerebellar hemispheres do not appear until the fifth month. The primitive fissures are not developed in the order of their relative size in the adult—thus the horizontal sulcus in the fifth month is merely a shallow groove. The best marked of the early fissures are: (a) the fissura prima between the developing culmen and declive, and (b) the fissura secunda between the future pyramid and uvula. The flocculus and nodule are developed from the rhombic lip, and are therefore recognizable as separate portions before any of the other cerebellar lobules. The groove produced by the bending over of the rhombic lip is here known as the floccular fissure; when the two lateral walls fuse, the right and left floccular fissures join in the middle line and their central part becomes the post-nodular fissure."



Transverse section of a cerebellar folium. ([Cajal](#))

Researcher timeline based on a recent review on cerebellum<sup>[24]</sup>

- Rolando - role in movement control
- Flourens - role in movement coordination
- Purkinje (1837) - histology of the cerebellar cortex
- Luciani (1891) - cerebellum has a tonic facilitating effect on central structures
- Bolk (1906) - localization for coordinating action on the motor system (medio-lateral organization)
- [Cajal](#) - histology of cortex circuitry
- Eccles and Ito - inhibitory interneurons and the Purkinje cells, excitatory connections of mossy and climbing afferents and granule cells

- Babinski and Holmes - anatomoclinical insights
- [Marr](#) and Albus - theories involving cognition and emotion
- Leiners and Dow
- [Magnus](#) - cerebellum no role in body posture

## Precerebellar Neurons

---

Precerebellar neurons (PCNs) are born in the hindbrain alar plate in the specific region called the rhombic lip (for review see <sup>[25]</sup>). From there they migrate by a process termed nucleokinesis<sup>[26]</sup>, extending a cytoplasmic process then move their nucleus.

In recent years a number of different chemotactic positive and negative factors have been suggested to have a role in driving the guided migration of these cells. Many signals are thought to be mediated through the Rho family GTPases links to the cytoskeleton.

- netrin-1<sup>[27]</sup>
- Slit
- Nr-CAM
- Calm1 signaling pathway<sup>[18]</sup>

## Cerebellar Nuclei

---

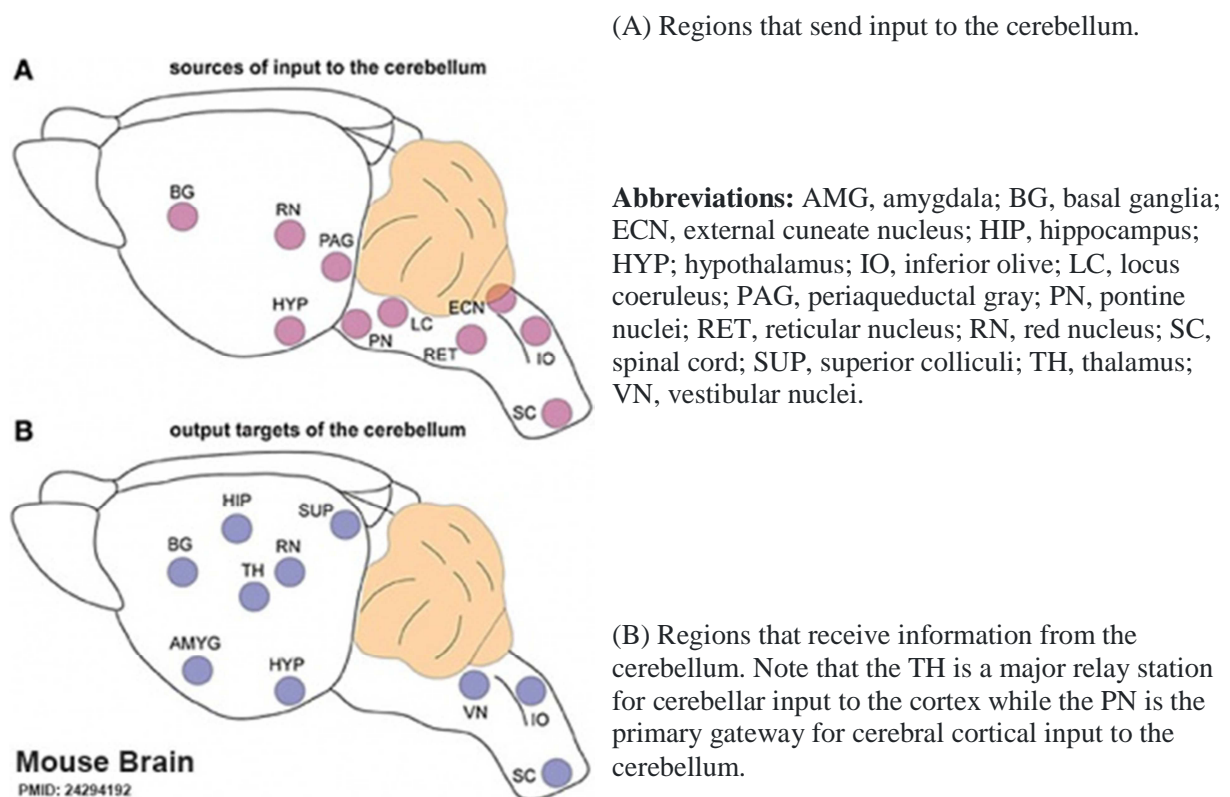
Cerebellar Nuclei		
Nucleus/Nuclei	Location	Function
<b>Fastigial Nucleus</b>	Most medially located of the cerebellar nuclei.	Receives input from the vermis and cerebellar afferents that carry vestibular, proximal somatosensory, auditory and visual information.
<b>Interposed Nuclei</b>	Consists of emboliform nucleus and globose nucleus. Interposed nuclei are situated laterally with respect to the fastigial nucleus.	Receives input from intermediate zone and cerebellar afferents that carry spinal, proximal somatosensory, auditory and visual information.
<b>Dentate Nucleus</b>	Largest of the cerebellar nuclei. Lateral to interposed nuclei.	Receives input from lateral hemisphere and cerebellar afferents that carry information from cerebral cortex.
<b>Vestibular Nuclei</b>	Located outside cerebellum in the medulla.	Considered to be cerebellar nuclei as their connectivity patterns are identical to those of cerebellar nuclei. Receive input from flocculonodular lobe and from the vestibular labyrinth.

**Links:** cerebellum

---

## Cerebellar Pathways

---



Cerebellum connections to the brain and spinal cord (mouse).<sup>[28]</sup>

## Molecular

---

- **Calm1** - signaling pathway is essential for the migration of mouse precerebellar neurons.<sup>[18]</sup>
- **Merlin** - impacts on cerebellar pre- and post-synaptic terminal organisation, not the overall cerebellar development.<sup>[29]</sup>
- **sonic hedgehog** - signaling by Bergmann glia is required for proper cerebellar cortical expansion and architecture.<sup>[15]</sup>

## Abnormalities

### Dandy-Walker Syndrome

Dandy-Walker Syndrome/Malformation (DWS) is a cerebellar hypoplasia and upward rotation of the cerebellar vermis with ventricular enlargement (cystic dilation of the fourth ventricle). Named in 1954 after the earlier identification by Walter **Dandy** (1914) and Arthur Earl **Walker** (1942), two USA neurosurgeons.

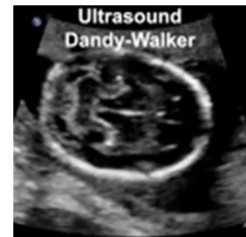
Walter Dandy (1886 – 1946) Arthur Earl Walker (1907 – 1995).

[International Classification of Diseases Q03 Congenital hydrocephalus](#) Incl.: hydrocephalus in newborn Excl.: Arnold-Chiari syndrome (Q07.0) hydrocephalus: acquired (G91.-) due to congenital toxoplasmosis (P37.1) with spina bifida (Q05.0-Q05.4)

- Q03.0 Malformations of aqueduct of Sylvius Aqueduct of Sylvius: anomaly obstruction, congenital stenosis
- Q03.1 Atresia of foramina of Magendie and Luschka Dandy-Walker syndrome

**Links:** [MP4 movie](#) | [Neural Abnormalities](#) | Cerebellum

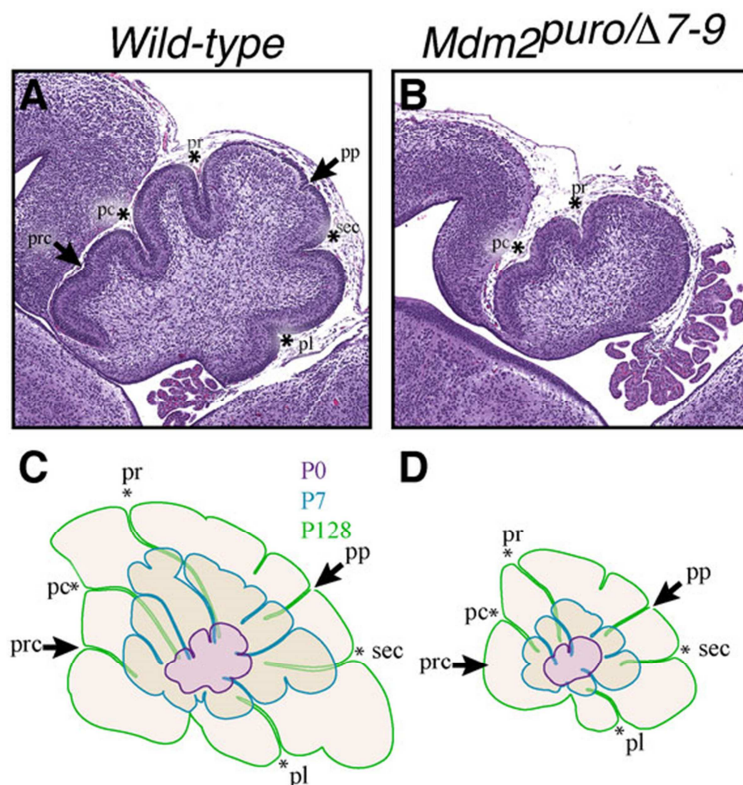
Development | [Ultrasound](#) | [OMIM - Dandy-Walker Syndrome](#) | [Movies](#)



**Dandy-Walker**

[Page](#) | [Play](#)

### Foliation Defects



## Mouse Cerebellar Foliation Defects<sup>[30]</sup>

(A–B) Midsagittal sections of newborn (P0) wild-type and Mdm2<sup>puro</sup>/Δ7-9 cerebella stained with H&E. (C–D) Superimposition of P0 (purple outline), P7 (blue outline), and adult (green outline) cerebella from wild-type (C) or Mdm2<sup>puro</sup>/Δ7-9 (D) mice. By P7, all four primary fissures, as well as two additional fissures, are evident in Mdm2<sup>puro</sup>/Δ7-9 mice. Moreover, even in adulthood, the mutant cerebellum does not reach the size or complexity of the wild-type cerebellum. Abbreviations are: prc, precentral; pc, preculminate; pr, primary; pp, prepyramidal; sec, secondary; pl, posterolateral fissures.

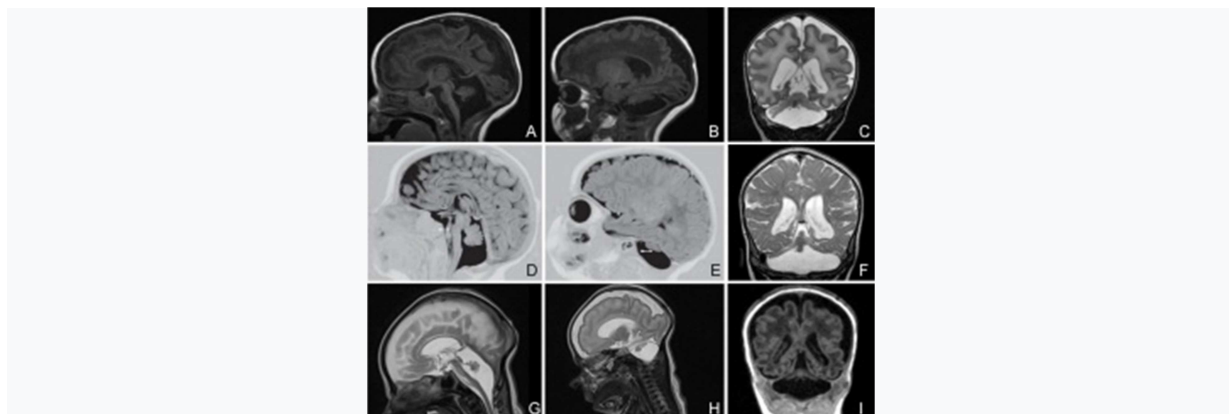
## Joubert Syndrome

Joubert syndrome (Joubert-Boltshauser syndrome, Cerebelloparenchymal disorder 4, Cerebellar vermis agenesis) is a rare disease of the cerebellum. Identified as a ciliopathy, characterized by the absence or underdevelopment of the cerebellar vermis, that controls balance and coordination. There is also malformation of the stem, connecting the brain and spinal cord. A recent super-resolution microscopy study has shown that the syndrome is caused by disruption of the ciliary transition-zone architecture.<sup>[31]</sup> Ciliopathies are a class of cell abnormalities that can be caused by mutations in components of the cellular transition zone, a domain near the base of the cilium, that controls the protein composition of its membrane.

- hypotonia - weak muscle tone
- ataxia - difficulty coordinating movements
- hyperpnea - episodes of fast breathing (improves with age and usually disappears around 6 months of age)
- oculomotor apraxia - difficulty moving the eyes from side to side.
- language and motor skills
- mild to severe intellectual disability
- distinctive facial features - broad forehead, arched eyebrows, droopy eyelids (ptosis), widely spaced eyes, low-set ears, and a triangular-shaped mouth.

**Links:** [NIH - Rare Diseases](#)

## Pontocerebellar Hypoplasia



## Pontocerebellar Hypoplasia (MRI)<sup>[32]</sup>

Pontocerebellar Hypoplasia (PCH) are very rare, inherited progressive neurodegenerative disorders with prenatal onset (for recent review see<sup>[32]</sup>). The major features are: hypoplasia or atrophy of cerebellum and pons, progressive microcephaly, and variable cerebral involvement. There is a further classification of 7 different subtypes (PCH1-7) and there is prenatal testing for the related inherited mutations.

- **PCH2, PCH4, PCH5** - Mutations in the 3 tRNA splicing endonuclease subunit genes.
- **PCH6** - Mutations in the nuclear encoded mitochondrial arginyl- tRNA synthetase gene.
- **PCH1** - Mutations in the tRNA splicing endonuclease, the mitochondrial arginyl- tRNA synthetase and the vaccinia related kinase1.

## Medulloblastoma

Medulloblastomas are the most common childhood primary central nervous system tumour. They are thought to arise in the developing cerebellum from the precursors of the granule cell.

## Rhombencephalosynapsis

Rhombencephalosynapsis (RES) is a unique cerebellar malformation characterized by fusion of the cerebellar hemispheres with partial or complete absence of a recognizable cerebellar vermis.<sup>[33]</sup>

- craniofacial features - prominent forehead, flat midface, hypertelorism, ear abnormalities
- somatic malformations - [heart](#), [kidney](#), spine, and [limb](#) defects.

## Brain Function

A recent consensus paper on experimental neurostimulation of the cerebellum suggests that this may be a target for symptomatic alleviation a number of neurological conditions.<sup>[34]</sup> These neurological and neuropsychiatric conditions include: ataxia, dystonia, essential tremor, Parkinson's disease (PD), epilepsy, stroke, multiple sclerosis, autism spectrum disorders, dyslexia, attention deficit hyperactivity disorder (ADHD), and schizophrenia.

## References

---

1. ↑ [Jump up to: 1.0 1.1 1.2](#) Haldipur P, Bharti U, Alberti C, Sarkar C, Gulati G, Iyengar S, Gressens P & Mani S. (2011). Preterm delivery disrupts the developmental program of the cerebellum. *PLoS ONE* , 6, e23449. PMID: [21858122](#) [DOI](#).
2. ↑ Priller J, Persons DA, Klett FF, Kempermann G, Kreutzberg GW & Dirnagl U. (2001). Neogenesis of cerebellar Purkinje neurons from gene-marked bone marrow cells in vivo. *J. Cell Biol.* , 155, 733-8. PMID: [11724815](#) [DOI](#).
3. ↑ Herculano-Houzel S, Catania K, Manger PR & Kaas JH. (2015). Mammalian Brains Are Made of These: A Dataset of the Numbers and Densities of Neuronal and Nonneuronal Cells in the Brain of Glires, Primates, Scandentia, Eulipotyphlans, Afrotherians and Artiodactyls, and Their Relationship with Body Mass. *Brain Behav. Evol.* , 86, 145-63. PMID: [26418466](#) [DOI](#).



4. ↑ Herculano-Houzel S. (2010). Coordinated scaling of cortical and cerebellar numbers of neurons. *Front Neuroanat* , 4, 12. PMID: [20300467](#) DOI.
5. ↑ LARSELL O. (1946). The cerebellum of cyclostomes. *Anat. Rec.* , 94, 478. PMID: [21020604](#)
6. ↑ LARSELL O. (1952). The morphogenesis and adult pattern of the lobules and fissures of the cerebellum of the white rat. *J. Comp. Neurol.* , 97, 281-356. PMID: [12999992](#) DOI.
7. ↑ LARSELL O & WHITLOCK DG. (1952). Further observations on the cerebellum of birds. *J. Comp. Neurol.* , 97, 545-66. PMID: [13034933](#) DOI.
8. ↑ LARSELL O. (1954). The development of the cerebellum of the pig. *Anat. Rec.* , 118, 73-107. PMID: [13124788](#) DOI.
9. ↑ LARSELL O. (1948). The development and subdivisions of the cerebellum of birds. *J. Comp. Neurol.* , 89, 123-89. PMID: [18889711](#) DOI.
10. ↑ LARSELL O. (1947). The cerebellum of myxinoids and petromyzonts including developmental stages in the lampreys. *J. Comp. Neurol.* , 86, 395-445. PMID: [20239748](#) DOI.
11. ↑ LARSELL O & STOTLER WA. (1947). Some morphological features of the human cerebellum. *Anat. Rec.* , 97, 352. PMID: [20341845](#)
12. ↑ LARSELL O. (1947). The development of the cerebellum in man in relation to its comparative anatomy. *J. Comp. Neurol.* , 87, 85-129. PMID: [20267600](#) DOI.
13. ↑ Xu F, Ge X, Shi Y, Zhang Z, Tang Y, Lin X, Teng G, Zang F, Gao N, Liu H, Toga AW & Liu S. (2020). Morphometric development of the human fetal cerebellum during the early second trimester. *Neuroimage* , 207, 116372. PMID: [31751665](#) DOI.
14. ↑ Yawno T, Sutherland AE, Pham Y, Castillo-Melendez M, Jenkin G & Miller SL. (2019). Fetal Growth Restriction Alters Cerebellar Development in Fetal and Neonatal Sheep. *Front Physiol* , 10, 560. PMID: [31191328](#) DOI.
15. ↑ [Jump up to:15.0 15.1](#) Cheng FY, Fleming JT & Chiang C. (2018). Bergmann glial Sonic hedgehog signaling activity is required for proper cerebellar cortical expansion and architecture. *Dev. Biol.* , 440, 152-166. PMID: [29792854](#) DOI.
16. ↑ Kalinichenko SG & Pushchin II. (2018). The modular architecture and neurochemical patterns in the cerebellar cortex. *J. Chem. Neuroanat.* , 92, 16-24. PMID: [29753860](#) DOI.
17. ↑ Poretti A, Boltshauser E & Huisman TA. (2016). Pre- and Postnatal Neuroimaging of Congenital Cerebellar Abnormalities. *Cerebellum* , 15, 5-9. PMID: [26166429](#) DOI.
18. ↑ [Jump up to:18.0 18.1 18.2](#) Kobayashi H, Saragai S, Naito A, Ichio K, Kawauchi D & Murakami F. (2015). *Calm1* signaling pathway is essential for the migration of mouse precerebellar neurons. *Development* , 142, 375-84. PMID: [25519244](#) DOI.
19. ↑ Hou C, Ding L, Zhang J, Jin Y, Sun C, Li Z, Sun X, Zhang T, Zhang A, Li H & Gao J. (2014). Abnormal cerebellar development and Purkinje cell defects in *Lgl1-Pax2* conditional knockout mice. *Dev. Biol.* , 395, 167-81. PMID: [25050931](#) DOI.
20. ↑ Huang GJ, Edwards A, Tsai CY, Lee YS, Peng L, Era T, Hirabayashi Y, Tsai CY, Nishikawa S, Iwakura Y, Chen SJ & Flint J. (2014). Ectopic cerebellar cell migration causes maldevelopment of Purkinje cells and abnormal motor behaviour in *Cxcr4* null mice. *PLoS ONE* , 9, e86471. PMID: [24516532](#) DOI.
21. ↑ Muguruma K, Nishiyama A, Ono Y, Miyawaki H, Mizuhara E, Hori S, Kakizuka A, Obata K, Yanagawa Y, Hirano T & Sasai Y. (2010). Ontogeny-recapitulating generation and tissue integration of ES cell-derived Purkinje cells. *Nat. Neurosci.* , 13, 1171-80. PMID: [20835252](#) DOI.
22. ↑ Cho KH, Rodríguez-Vázquez JF, Kim JH, Abe H, Murakami G & Cho BH. (2011). Early fetal development of the human cerebellum. *Surg Radiol Anat* , 33, 523-30. PMID: [21380713](#) DOI.
23. ↑ HERNDON RM. (1964). THE FINE STRUCTURE OF THE RAT CEREBELLUM. II. THE STELLATE NEURONS, GRANULE CELLS, AND GLIA. *J. Cell Biol.* , 23, 277-93. PMID: [14222815](#)



24. ↑ Voogd J & Koehler PJ. (2018). Historic notes on anatomic, physiologic, and clinical research on the cerebellum. *Handb Clin Neurol* , 154, 3-26. PMID: [29903448 DOI](#).
25. ↑ Bloch-Gallego E, Causeret F, Ezan F, Backer S & Hidalgo-Sánchez M. (2005). Development of precerebellar nuclei: instructive factors and intracellular mediators in neuronal migration, survival and axon pathfinding. *Brain Res. Brain Res. Rev.* , 49, 253-66. PMID: [16111554DOI](#).
26. ↑ Tsai LH & Gleeson JG. (2005). Nucleokinesis in neuronal migration. *Neuron* , 46, 383-8. PMID: [15882636 DOI](#).
27. ↑ Killeen MT & Sybingco SS. (2008). Netrin, Slit and Wnt receptors allow axons to choose the axis of migration. *Dev. Biol.* , 323, 143-51. PMID: [18801355 DOI](#).
28. ↑ Reeber SL, Otis TS & Sillitoe RV. (2013). New roles for the cerebellum in health and disease. *Front Syst Neurosci* , 7, 83. PMID: [24294192 DOI](#).
29. ↑ Toledo A, Lang F, Doengi M, Morrison H, Stein V & Baader SL. (2019). Merlin modulates process outgrowth and synaptogenesis in the cerebellum. *Brain Struct Funct* , , . PMID: [31165301 DOI](#).
30. ↑ Malek R, Matta J, Taylor N, Perry ME & Mendrysa SM. (2011). The p53 inhibitor MDM2 facilitates Sonic Hedgehog-mediated tumorigenesis and influences cerebellar foliation. *PLoS ONE* , 6, e17884. PMID: [21437245 DOI](#).
31. ↑ Shi X, Garcia G, Van De Weghe JC, McGorty R, Pazour GJ, Doherty D, Huang B & Reiter JF. (2017). Super-resolution microscopy reveals that disruption of ciliary transition-zone architecture causes Joubert syndrome. *Nat. Cell Biol.* , 19, 1178-1188. PMID: [28846093DOI](#).
32. ↑ [Jump up to:32.0 32.1](#) Namavar Y, Barth PG, Poll-The BT & Baas F. (2011). Classification, diagnosis and potential mechanisms in pontocerebellar hypoplasia. *Orphanet J Rare Dis* , 6, 50. PMID: [21749694 DOI](#).
33. ↑ Aldinger KA, Dempsey JC, Tully HM, Grout ME, Mehaffey MG, Dobyns WB & Doherty D. (2018). Rhombencephalosynapsis: Fused cerebellum, confused geneticists. *Am J Med Genet C Semin Med Genet* , 178, 432-439. PMID: [30580482 DOI](#).
34. ↑ Miterko LN, Baker KB, Beckinghausen J, Bradnam LV, Cheng MY, Cooperrider J, DeLong MR, Gornati SV, Hallett M, Heck DH, Hoebeek FE, Kouzani AZ, Kuo SH, Louis ED, Machado A, Manto M, McCambridge AB, Nitsche MA, Taib NOB, Popa T, Tanaka M, Timmann D, Steinberg GK, Wang EH, Wichmann T, Xie T & Sillitoe RV. (2019). Consensus Paper: Experimental Neurostimulation of the Cerebellum. *Cerebellum* , , . PMID: [31165428 DOI](#).

## Journals

- Cerebellum [Springer Publishers](#)

## Reviews

Lehman VT, Black DF, DeLone DR, Blezek DJ, Kaufmann TJ, Brinjikji W & Welker KM. (2020). Current concepts of cross-sectional and functional anatomy of the cerebellum: a pictorial review and atlas. *Br J Radiol* , 93, 20190467. PMID: [31899660 DOI](#).

Wang L & Liu Y. (2019). Signaling pathways in cerebellar granule cells development. *Am J Stem Cells* , 8, 1-6. PMID: [31139492](#)

Shoja MM, Jensen CJ, Ramdhan R, Chern J, Oakes WJ & Tubbs RS. (2018). Embryology of the Craniocervical Junction and Posterior Cranial Fossa Part II: Embryogenesis of the hindbrain. *Clin Anat* , , . PMID: [29344994 DOI](#).

Aldinger KA & Doherty D. (2016). The genetics of cerebellar malformations. *Semin Fetal Neonatal Med* , 21, 321-32. PMID: [27160001](#) [DOI](#).

Butts T, Green MJ & Wingate RJ. (2014). Development of the cerebellum: simple steps to make a 'little brain'. *Development* , 141, 4031-41. PMID: [25336734](#) [DOI](#).

Voogd J. (2012). A note on the definition and the development of cerebellar Purkinje cell zones. *Cerebellum* , 11, 422-5. PMID: [22396330](#) [DOI](#).

Roussel MF & Hatten ME. (2011). Cerebellum development and medulloblastoma. *Curr. Top. Dev. Biol.* , 94, 235-82. PMID: [21295689](#) [DOI](#).

Herculano-Houzel S. (2010). Coordinated scaling of cortical and cerebellar numbers of neurons. *Front Neuroanat* , 4, 12. PMID: [20300467](#) [DOI](#).

Ten Donkelaar HJ & Lammens M. (2009). Development of the human cerebellum and its disorders. *Clin Perinatol* , 36, 513-30. PMID: [19732611](#) [DOI](#).

Moldrich RX, Dauphinot L, Laffaire J, Rossier J & Potier MC. (2007). Down syndrome gene dosage imbalance on cerebellum development. *Prog. Neurobiol.* , 82, 87-94. PMID: [17408845](#) [DOI](#).

Zervas M, Blaess S & Joyner AL. (2005). Classical embryological studies and modern genetic analysis of midbrain and cerebellum development. *Curr. Top. Dev. Biol.* , 69, 101-38. PMID: [16243598](#) [DOI](#).

Sato T, Joyner AL & Nakamura H. (2004). How does Fgf signaling from the isthmic organizer induce midbrain and cerebellum development?. *Dev. Growth Differ.* , 46, 487-94. PMID: [15610138](#) [DOI](#).

Adamsbaum C, Merzoug V, André C, Ferey S & Kalifa G. (2003). [Imaging of the pediatric cerebellum]. *J Neuroradiol* , 30, 158-71. PMID: [12843872](#)

## Articles

Cho KH, Rodríguez-Vázquez JF, Kim JH, Abe H, Murakami G & Cho BH. (2011). Early fetal development of the human cerebellum. *Surg Radiol Anat* , 33, 523-30. PMID: [21380713](#) [DOI](#).

Lee EY, Ji H, Ouyang Z, Zhou B, Ma W, Vokes SA, McMahon AP, Wong WH & Scott MP. (2010). Hedgehog pathway-regulated gene networks in cerebellum development and tumorigenesis. *Proc. Natl. Acad. Sci. U.S.A.* , 107, 9736-41. PMID: [20460306](#) [DOI](#).

Corrales JD, Rocco GL, Blaess S, Guo Q & Joyner AL. (2004). Spatial pattern of sonic hedgehog signaling through Gli genes during cerebellum development. *Development* , 131, 5581-90. PMID: [15496441](#) [DOI](#).